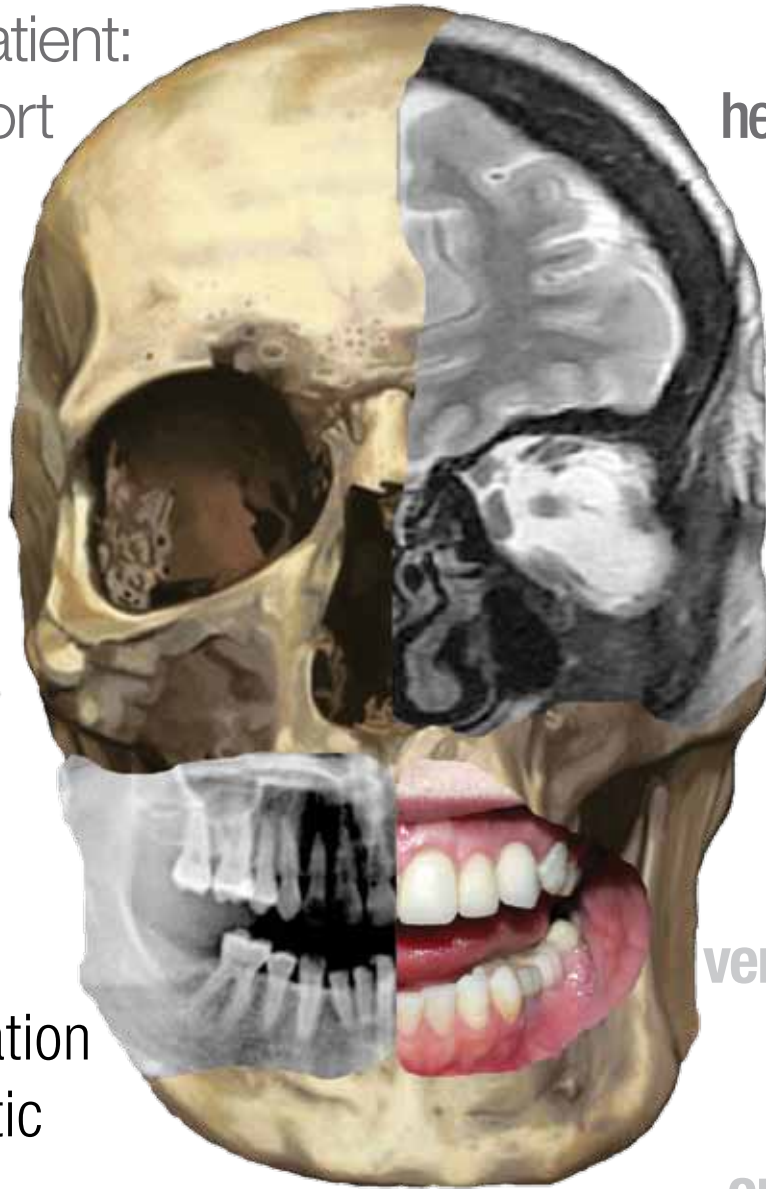

CDR

Columbia Dental Review

proper appliance in a pediatric patient:
a case report and review of the literature
periapical cemental dysplasia
and an adjacent compound odontoma
successful osseointegration and prosthetic loading of a temporomastoid



implant in the treatment of congenital hemi-anotia: a case presentation
management of tooth agenesis by orthodontic space closure: a case study
vander woude syndrome:
a case study treating a vertically deficient edentulous maxilla with onlay bone grafts and a maxillary overdenture





COLUMBIA UNIVERSITY
College of Dental Medicine

Columbia Dental Review 2010-2011

Editorial Board

Editor-in-Chief

Andy Wan '11

Editors

Jaqueline Haker '11

Renata Khelemsky '11

Gloria Lee '11

Lauren Midthun '11

Steven Nadler '11

Renee C. Reynolds '11

Rupali Shah '11

Violeta Vayner Kenigsberg '11

Assistant Editors

Cha Hur '12

Grace Sun Ae Hur '12

Caitlin Magraw '12

Paul Jones '12

Thailong B. Tran '12

Matthew Cozin '13

Camille Marquis '13

Jessica Lee '13

Erica Phillips '13

Ilana Stollow '13

Design and Layout

Richard V. Miller

Faculty Reviewers

Thomas J. Cangialosi, DDS

Steven Chussid, DDS

Martin J. Davis, DDS

Sidney B. Eisig, DDS

Shantanu Lal, DDS

Louis Mandel, DDS

Elizabeth Philipone, DMD

Letty Moss-Salentijn, DDS, PhD

George Shelby White, DDS, FACP

Angela J. Yoon, DDS

Aim and Scope

The Columbia Dental Review (CDR) is an annual publication of Columbia University College of Dental Medicine (CDM). This journal is intended to be a clinical publication, featuring case presentations supported by substantial reviews of the relevant literature. It is a peer-reviewed journal, edited by the students of the school. The editors are selected on the basis of demonstrated clinical scholarship. Authors are primarily CDM students and residents from pre-doctoral and postdoctoral programs. CDM faculty and attendings from affiliated hospitals are doctors of record of the patients who are presented. Peer reviewers are selected primarily from the CDM faculty. Instructions for authors wishing to submit articles for future editions of the CDR can be found on the last page of this journal. Opinions expressed by the authors do not necessarily represent the policies of the Columbia University College of Dental Medicine.

Editors' Note

Dear Readers,

For 15 years, the Columbia Dental Review has given the students at Columbia an opportunity to engage in a dialogue with the rest of the dental community. Through hard work and the guidance of faculty, we have been able to share unique and rare clinical cases that encompass both the different specialties and newest treatment modalities in dentistry. This publication represents CDM's commitment to collaboration, education, and providing optimal dental care supported by evidence based research. I am very grateful to be involved in this contribution to the profession.

The talent and work of many individuals have made the publication of this volume of CDR possible. I would like to thank the authors, faculty, reviewers, and editors for the submission and refinement of such interesting case presentations, the design team for the assemblage of a spectacular cover and layout, and Dr. Letty Miss-Salentijn for which her mentorship ensures CDR's endurance and continued service to the dental community.

Sincerely,

Andy Wan '11

CDR

Columbia Dental Review 2010-2011



COLUMBIA UNIVERSITY
College of Dental Medicine

Table of Contents

Groper Appliance in a Pediatric Patient: A Case Report and Review of the Literature <i>Ilana M. Stollow, Richard K. Yoon, DDS</i>	1
Periapical Cemental Dysplasia and an Adjacent Compound Odontoma <i>Gloria Lee, Steven R. Singer, DDS</i>	7
Management of Tooth Agenesis by Orthodontic Space Closure: A Case Study <i>Grace Sun Ae Hur, Jin Kim, DDS, MS, Jenny Zhu, DDS, MS, Ülkü Z. Ersoy, DDS, DMSc</i>	10
VanderWoude Syndrome: A Case Study <i>Justin Ohnigian, Kristen Lowe DDS, Ronnette Garcia DDS, MS</i>	17
Successful Osseointegration and Prosthetic Loading of a Temporomastoid Implant in the Treatment of Congenital Hemi-Anotia: A Case Presentation <i>Steven Nadler, Lauren Midthun, John H. Evans DDS, Yuko C. Nakamura DMD, MD, Candice Zernick DMD, MPH, MS</i>	23
Treating a Vertically Deficient Edentulous Maxilla with Onlay Bone Grafts and a Maxillary Overdenture <i>Paul Jones Jr, Ray Jone DDS, Jason J. Psillakis DDS, MS</i>	31

Groper Appliance in a Pediatric Patient: A Case Report and Review of the Literature

Ilana M. Stollow¹, Richard K. Yoon, DDS²

¹Class of 2013, Columbia University College of Dental Medicine, New York City, New York

²Associate Professor and Residency Director, Pediatric Dentistry

Columbia University College of Dental Medicine, New York City, New York

Abstract

Premature loss of primary anterior teeth occurs frequently due to severe early childhood dental caries and dental trauma. Different treatment options exist to replace missing primary teeth, and the use of a fixed anterior esthetic appliance is one alternative for replacing the primary incisor teeth until the successors erupt. This paper tabulates case reports of very young children with primary anterior teeth problems and summarizes the authors' approaches and outcomes. In addition, a case report is presented for the approach to and outcome for a 3-year-old male with extensive early childhood dental caries.

Introduction

Space management after the premature loss of primary teeth is an essential element of dentistry. Space maintaining appliances are customarily used after the premature loss of posterior teeth to maintain proper function and preserve existing arch length.¹ Loss of arch length may lead to problems such as crowding, ectopic eruption, dental impaction, cross-bite formation, and dental midline discrepancies. The premature loss of primary anterior teeth does not readily cause space loss, and therefore does not by and large indicate the need for space management. The parent may request one for esthetic reasons.^{1,2} The use of anterior esthetic appliances becomes significant when young pre-school children become increasingly conscious of their appearance.²

A fixed anterior bridge can be used to replace prematurely missing primary anterior teeth if esthetics is of concern to the parent. It consists of a lingual arch wire soldered to bands placed on the primary second molars. In the anterior region, the arch wire is soldered to each individual tooth or unit. The fixed anterior bridge provides the advantages of esthetics and prevention of untimely removal, breakage, or loss of the appliance.¹ Also described is the placement of a fixed anterior bridge in a very young child patient with extensive dental caries treated under general anesthesia in the operating room.

Case Report

A 3-year-old male presented with his parents for an initial dental consult. The patient exhibited extensive dental caries as a consequence of unrestricted nursing bottle use. The child patient was taken to the operating room (New York-Presbyterian Morgan Stanley-Komansky Children's Hospi-

tal) for full mouth oral rehabilitation under general anesthesia due to his very young age, pre-cooperative behavior, and the extent of the dental treatment protocol. The dental treatment involved multiple restorations, pulpotomies, and stainless steel crowns on all posterior first molars, multiple resin composite restorations on all posterior second molars, and extractions and incision and drainage of the tissue surrounding the abscessed six maxillary primary incisors (C, D, E, F, G, and H). Once the maxillary posterior stainless steel crowns were cemented with a glass ionomer fluoride releasing cement, molar bands were gently fitted and contoured to the patient's now restored first and second maxillary primary molar teeth. A maxillary alginate mold was completed; the molar bands removed and gently fixed to the impression with paper clips and wrapped in a moist paper towel and sealed in a plastic bag to pour and prepare at a later hour the same day. The patient tolerated the procedure well, was extubated in the operating room, was admitted to the recovery room, and was discharged after meeting all hospital discharge criteria. A maxillary stone model was prepared in the office and sent to a laboratory for fabrication of a fixed anterior bridge (*Figure A, B*). Three weeks later, the appliance was cemented intraorally with a fluoride releasing glass ionomer cement (*Figure C, D*). The patient was followed at routine recall examinations biannually to ensure that the appliance was comfortable, not interfering with normal hygiene, and not preventing the eruption of the succedaneous maxillary incisors. On recall, when eruption of the permanent maxillary incisors was expected at age 6.5 years, a maxillary occlusal radiograph (*Figure E*) was taken to visualize them. At that point, the incisors were noted to be nearing eruption; therefore, the fixed anterior bridge was removed (*Figure F*) and the remaining cement removed and the teeth were polished. Within two months, the maxillary incisors erupted into the oral cavity (*Figure G*).

Discussion

Options exist to replace prematurely missing primary anterior teeth. Depending on considerations such as the patient's age, behavior, and general oral health, treatment options include a removable pediatric partial denture with clasps or different types of fixed space maintainers. In this clinical report, early childhood caries, particularly from frequent bottle use, thick accumulations of bacterial plaque, and a lack of oral hygiene by the parent, are factors predisposing to early childhood caries and premature tooth loss. When

Groper Appliance in a Pediatric Patient: A Case Report and Review of the Literature

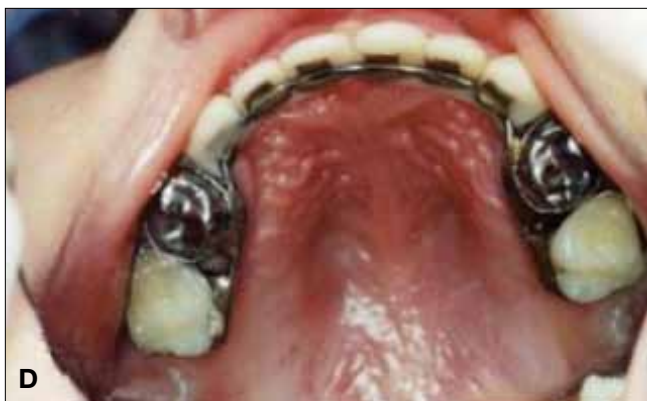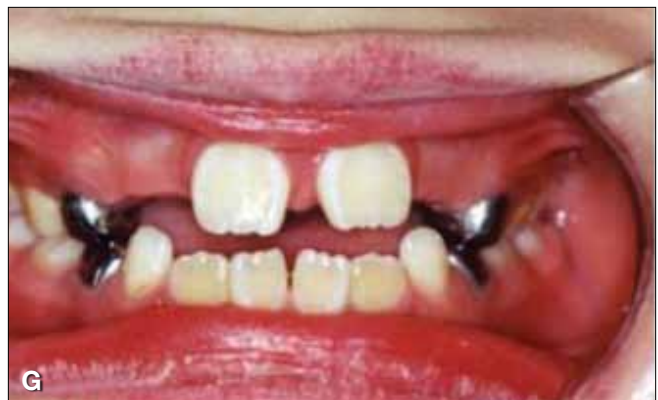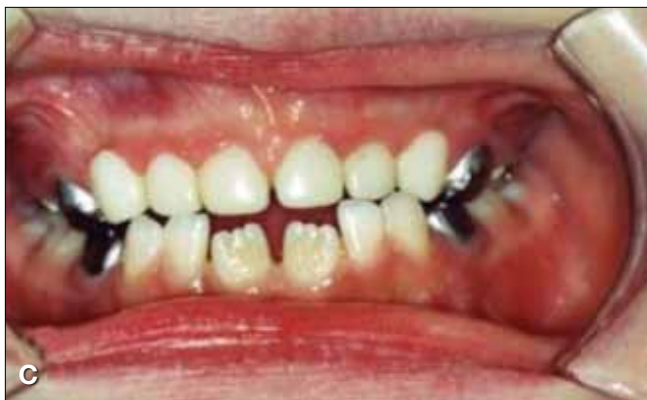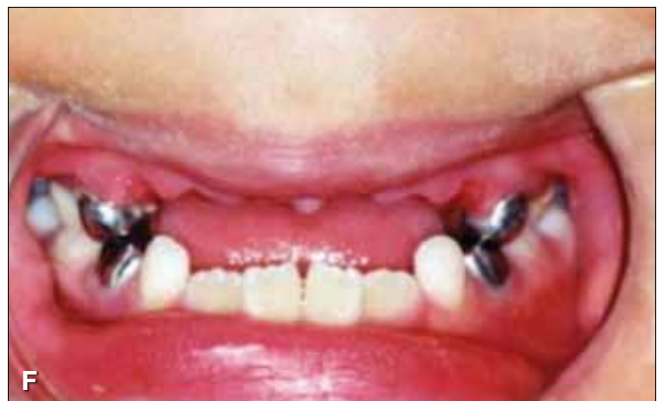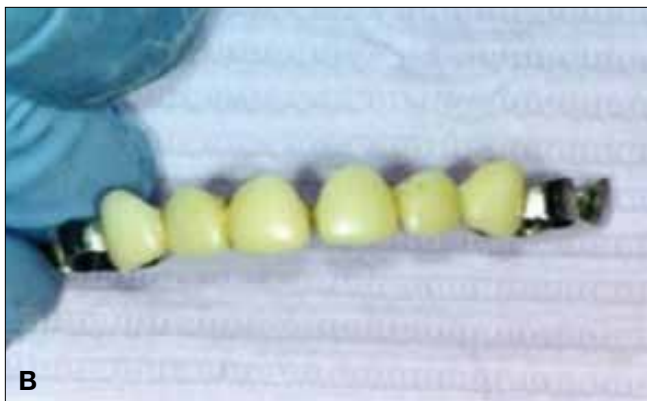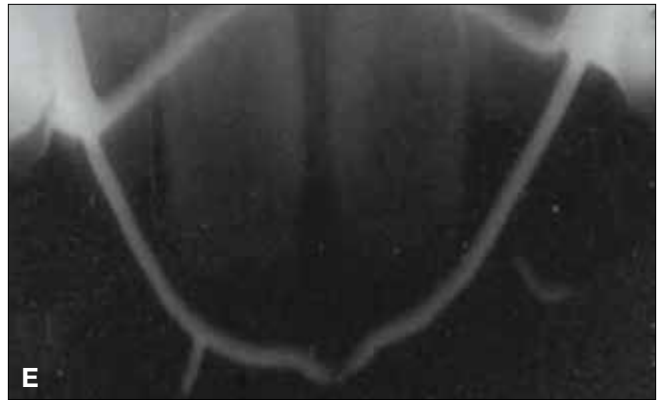


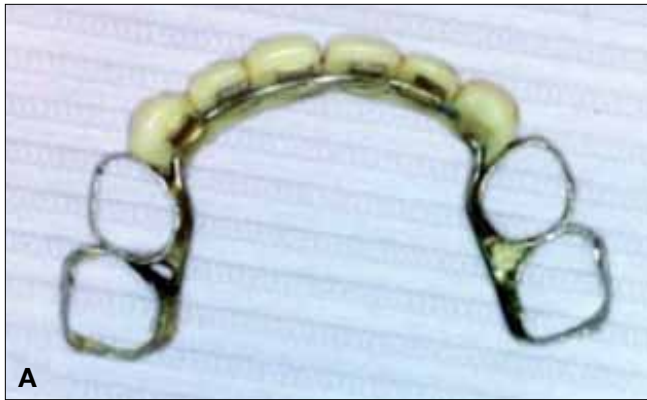Figure A Occlusal view of Groper fixed anterior bridge appliance. The anterior bridge is made strong by attaching each tooth separately to a specifically designed stainless steel pad. Each unit is then welded and soldered to the arch wire.

Figure B Frontal view of Groper fixed anterior bridge appliance. Esthetics are key advantages.

Figure C Frontal view of appliance inserted.

Figure D Occlusal view of appliance inserted.

Figure E Occlusal radiograph taken to view position of maxillary permanent incisors and to determine correct timing of appliance removal.

Figure F Appliance removed prior to eruption of permanent incisors.

Figure G Eruption of permanent central incisors 6 months after appliance removal.

Groper Appliance in a Pediatric Patient: A Case Report and Review of the Literature

Table 1: Tabulation of 29 Cases for Maxillary Anterior Primary Teeth

Author	Year	Sex	Age	Medical History	Diagnosis	Treatment	Outcome
<i>Restorative Approach</i>							
1. Navit et al ⁵	2010	F	3 Y	Well-child	Caries	Pulpectomy, post and core, resin crown	Restoration intact at 3 month recall
2. Bayrak et al ⁶	2009	F	4 Y	Well-child	Caries	Pulpectomy, post and core, resin crown	Not reported
3. De Carvalho Rocha et al ⁷	2008	F	3 Y	Well-child	Trauma	Endodontic treatment and composite resin restoration	Normal eruption of permanent teeth
4. Kapur et al ⁸	2005	F	4.5 Y	Well-child	Caries	Pulpectomy, post and core, resin crown	Not reported
5. Motisuki et al ⁹	2005	--	3 Y	Well-child	Caries	Resin crowns reinforced with fiberglass posts	Discoloration, but no radiographic signs of pathology at 12 month recall
6. Mandrolj ¹⁰	2003	M	3 Y	Well-child	Caries	Endodontic treatment, intra-canal retainers, natural crowns	Clinical success recovered function and esthetics
7. Updyke et al ¹¹	2001	--	3 Y	Well-child	Caries	Preformed composite resin crowns	Not reported
8. Ramires-Romito et al ¹²	2000	M	3 Y	Well-child	Caries	Pulpectomy, post and core, and natural crowns	Clinical success—recovered function and esthetics
9. Carranza et al ¹³	1999	M	3 Y	Well-child	Caries	Pulpotomies, pin-retained composite restorations	Excellent esthetic results at 2-year follow up
10. Carranza et al ¹³	1999	M	4 Y	Well-child	Caries	Pulpotomy and pin-retained composite restoration Resin-based composite veneers	Slight restoration defect and pins showing through the composite without compromising esthetics after 4 years
11. Holan ¹⁴	1999	F	4 Y	Well-child	Trauma	Repositioning and splinting Pulpectomy and caries removal with composite resin restoration	Maxillary primary central incisors were mobile and displaced at 7 years of a root resorption of these teeth seen in radiographs. A few months later, permanent successors erupted with mild hypocalcification
12. Wanderley et al ¹⁵	1999	F	3 Y	Well-child	Caries	Endodontic treatment, post and core, and indirect resin crowns	No signs of fracture at 10-month follow up
13. Weiger et al ¹⁶	1999	F	3 Y	Well-child	Trauma	Reimplantation/Splint Endodontic treatment	Fistula developed and external root resorption occurred at 18-month follow up. Primary central incisor extracted. Eruption of permanent central incisor 6 months after extraction of deciduous tooth at 33-month follow up
14. Ram et al ¹⁷	1994	M	1 Y	Well-child	Trauma	Partial pulpotomy, restoration	No sensitivity, discoloration or mobility at 21-week follow up Dentinal bridge formation and continuing root development

Groper Appliance in a Pediatric Patient: A Case Report and Review of the Literature

Table 1: **Tabulation of 29 Cases for Maxillary Anterior Primary Teeth** (continued)

Author	Year	Sex	Age	Medical History	Diagnosis	Treatment	Outcome
<i>Space Maintenance Approach</i>							
15. Tannure et al ¹⁸	2009	F	3 Y	Well-child	Trauma	Removable anterior space maintainer	Space maintainer intact at 12 month recall
16. Tannure et al ¹⁸	2009	M	4 Y	Well-child	Trauma	Extraction and removable anterior space maintainer	Space maintainer intact at 12 month recall
17. Freitas et al ¹⁹	2008	M	6 Y	Well-child	Trauma	Removable anterior space maintainer	Appliance intact during recall visits
18. Usha et al ²⁰	2007	F	4 Y	Well-child	Caries	Extraction and anterior removable space maintainer for central incisors Pulpectomy with composite restoration using custom made posts for lateral incisors	Not reported
19. Oliveira et al ²¹	2006	—	5 Y	Well-child	Caries	Anterior space maintainer and resin veneers	Restorations and space maintainer intact at recall visits
20. Kapur et al ⁸	2005	F	5	Well-child	Trauma	Fixed anterior space maintainer for upper right central incisor Pulpectomy, post and core, and resin restorations for upper left central incisor	Restoration and space maintainer intact at 3 month recall
21. Kapur et al ⁸	2005	M	5	Well-child	Caries	Pulpectomy and anterior maxillary overdenture	Restoration and space maintainer intact at 3 month recall
22. Chang et al ²²	1999	—	5 Y	Well-child	Caries	Anterior space maintainer	Not reported
23. Huber ²³	1997	M	4 Y	Well-child	Trauma	Resin-bonded retainer	Appliance served its purpose at 1-year follow up
24. Baroni et al ²⁴	1992	F	3 Y	Well-child	Caries	Fixed anterior space maintainer	Appliance eventually removed once permanent teeth positioned correctly
25. Laird ²⁵	1970	F	4	Well-child	Caries	Immediate anterior maxillary denture	Patient pleased with appearance and 2 months later a new denture was made
<i>No Treatment</i>							
26. Torriani et al ²⁶	2008	M	2.5 Y	Well-child	Trauma	Wait for re-eruption	Normal eruption of permanent teeth
27. Lenzi et al ²⁷	2006	M	5 Y	Well-child	Trauma	Reposition/Splint	Hypoplastic permanent incisors
28. Cunha et al ²⁸	2001	M	1 Y	Well-child	Trauma	Reposition	None reported at 13 month follow up.

Groper Appliance in a Pediatric Patient: A Case Report and Review of the Literature

such a diagnosis is made, parents are presented with a few treatment options: (1) dental extractions with no appliance, because there is limited space loss with the premature loss of primary anterior teeth, (2) if restorable, pulpectomy and/or restorative treatment with a resin composite restoration, or (3) dental extractions and fabrication of a removable or fixed esthetic appliance. If the success of endodontic therapy is doubtful, or if there is a lack of tooth structure, extraction and the use of an esthetic appliance is a practical alternative.³

The selection of whether an appliance should be removable or fixed depends on the child's stage of dental development, the dental arch involved, the location of the missing primary teeth, and the oral hygiene status.⁴ While removable space maintainers are easier to clean, allowing better oral hygiene maintenance than fixed appliances, removable maintainers depend somewhat on patient compliance and may be taken out, lost, or broken easily, especially at a very young age. Consequently, fixed maintainers, which are worn continuously for long periods of time, may be preferable.^{1,4}

Fixed space maintaining appliances may contribute to tooth surface plaque retention and even decalcification in patients at risk for dental caries. A review performed by Laing et al. concluded that practitioners monitoring the developing dentition should recommend space maintainers on an individual needs basis, weighing the occlusal disturbances that may result without one versus the potential for plaque accumulation and new caries that may develop as a result of a fixed appliance.²

Table 1 summarizes twenty-eight case reports in the literature of young children ages 1 to 5 years with primary anterior teeth problems. Children diagnosed either with caries, missing anterior teeth due to trauma, or congenitally missing anterior teeth were provided different treatment approaches. Seven cases describe patients whose treatment comprised only receiving a space maintaining appliance^{18,19,22,23,24,25} and those cases that document follow-up describe the patient as satisfied esthetically and functionally and the appliance as intact during recall visits. Four cases describe patients who received both an esthetic appliance and primary tooth endodontic treatment and restoration.^{8, 20,21} All cases with follow-up describe the restoration and space maintainer as intact at recall visits. Fourteen cases describe patients who received only primary tooth endodontic treatment and restoration.^{5,6,7,8,9,10,11,12,13,14, 15,16,17} Three of those did not report outcomes.^{6,8,11} Seven reported esthetic and functional success at recall visits or normal eruption of permanent successors.^{5,7,10,12,13,15,17} One case resulted in tooth discoloration, but demonstrated no signs of radiographic or clinical pathology after 12 months.⁹ One case had a slight defect in a restoration, but had uncompromised esthetics after four years.¹³ Another case demonstrated tooth mobility and displace-

ment, root resorption several years after the restoration, and mild hypocalcification of successor teeth.¹⁴ Another case resulted in external root resorption of the primary tooth and the development of a fistula. This tooth was extracted, and the permanent successor tooth erupted.¹⁶ Three cases describe patients who received repositioning of luxated teeth or replantation of teeth that were traumatically avulsed.^{26,27,28} One case resulted in successful eruption of permanent successors,²⁶ and another reported no complications at the 13-month follow-up.²⁸ A third case resulted in hypoplastic permanent incisors.²⁷

A significant number of patients (11/29 or approximately 40%) received extractions and space maintainers with good outcomes. The clinical report presented here demonstrates the use of a fixed anterior bridge after comprehensive dental rehabilitation. A fixed appliance was chosen rather than a removable appliance due to the lack of oral hygiene compliance and the child's uncooperative behavior. The appliance was effective for this child patient for approximately 3.5 years. One common complication is loss of retention of the appliance over time. This particular case demonstrated the use of two bands on both sides to help prevent this common occurrence. Another method to prevent retention loss is the placement of occlusal rest seats on the primary molars to distribute occlusal forces and then to bond the rests into place.

Conclusion

Treatment options exist to manage prematurely lost primary anterior teeth. Space loss due to missing primary anterior teeth is minimal or inconsequential. Many parents do desire esthetically pleasing replacement alternatives. The anterior esthetic appliance is a practical and viable option for that purpose. This paper reviews the literature of reported cases of prematurely lost primary anterior tooth management and documents one pediatric patient for whom the fixed anterior bridge appliance resulted in clinical success.

References

1. Bijoor R, Kohli K. Contemporary space maintenance for the pediatric patient. *NY State Dent J* 2005;71(2):32-5.
2. Laing E, Ashley P, Naini FB, Gill DS. Space maintenance. *Int J Paediatr Dent* 2009;19(3):155-62.
3. Baroni C, Rimondini L. Space maintenance and endodontic follow-up: Case reports. *J Clin Pediatr Dent* 1992;16(2):94-7.
4. Subramaniam P, Babu G, Sunny R. Glass fiber-reinforced composite resin as a space maintainer: a clinical study. *J Indian Soc Pedod Prev Dent* 2008;26;Suppl3:S98-103.

Groper Appliance in a Pediatric Patient: A Case Report and Review of the Literature

5. Navit S, Katiyar A, Samadi F, Jaiswal JN. Rehabilitation of severely mutilated teeth under general anesthesia in an emotionally immature child. *J Indian Soc Pedod Prev Dent* 2010;28(1):42-4.
6. Bayrak S, Tunc E, Tuloglu N. Polyethylene fiber-reinforced composite resin used as a short post in severely decayed primary anterior teeth: A case report. *Oral Surg Oral Med Oral Pathol Oral Radiol Endod* 2009;107(5):e60-4.
7. De Carvalho Rocha MJ, Cardoso M. Reimplantation of primary tooth—case report. *Dent Traumatol* 2008;24(4):e4-10.
8. Kapur A, Chawla HS, Ashima G, Krishan G. An esthetic point of view in very young children. *J Clin Pediatr Dent* 2005;30(2):99-104.
9. Motisuki C, Santos-Pinto L, Giro EMA. Restoration of severely decayed primary incisors using indirect composite resin restoration technique. *Int J Paediatr Dent* 2005;15(4):282-6.
10. Mandroli PS. Biologic restoration of primary anterior teeth: a case report. *J Indian Soc Pedod Prev Dent* 2003;21(3):95-7.
11. Updyke J, Sneed WD. Placement of a preformed indirect resin composite shell crown: a case report. *Pediatr Dent* 2001;23(2):143-4.
12. Ramires-Romito AC, Wanderley MT, Oliveira MD, Imparato JC, Correa MS. Biologic restoration of primary anterior teeth. *Quintessence Int* 2000;31(6):405-11.
13. Carranza F, Garcia-Godoy F. Esthetic restoration of primary incisors. *Am J Dent* 1999;12(2):55-8.
14. Holan G. Conservative treatment of severely luxated maxillary primary central incisors: case report. *Pediatr Dent* 1999;21(7):459-62.
15. Wanderley MT, Ferreira SL, Rodrigues CR, Rodrigues Filho LE. Primary anterior tooth restoration using posts with macro-retentive elements. *Quintessence Int* 1999;30(6):432-6.
16. Weiger R, Heuchert T. Management of an avulsed primary incisor. *Endod Dent Traumatol* 1999;15(3):138-43.
17. Ram D, Holan G. Partial pulpotomy in a traumatized primary incisor with pulp exposure: case report. *Pediatr Dent* 1994;16(1):44-8.
18. Tannure P, Valinoti A, Maia L. The use of a natural tooth crown following traumatic injuries in primary dentition. *J Clin Pediatr Dent* 2009;33(4):275-8.
19. Freitas MC, de Castilho AR, Marta SN, Francischone LA, Carrara CE, Franzolin Sde O. Consequences and treatment after multiple avulsions of deciduous teeth—a case report. *Dent Traumatol* 2008;24(3):e381-4.
20. Usha M, Deepak V, Venkat S, Gargi M. Treatment of severely mutilated incisors: a challenge to the pedodontist. *J Indian Soc Pedod Prev Dent* 2007;25(Suppl):S34-6.
21. Oliveira LB, Tamay TK, Oliveira MD, Rodrigues CM, Wanderley MT. Human enamel veneer restoration: an alternative technique to restore primary teeth. *J Clin Pediatr Dent* 2006;30(4):277-9.
22. Chang JZ, Chen PH, Kuo SC. An appliance to replace prematurely lost maxillary anterior teeth using double stainless steel crowns on abutment teeth. *J Clin Pediatr Dent* 1999;23(4):285-8.
23. Huber CT. Resin-bonded retainer for replacement of an avulsed primary incisor: a case report. *Quintessence Int* 1997;28(5):337-9.
24. Baroni C, Rimondini L. Space maintenance and endodontic follow-up: case reports. *J Clin Pediatr Dent* 1992;16(2):94-7.
25. Laird WR. Immediate dentures for children. *J Prosthet Dent* 1970;24(4):358-61.
26. Torriani DD, Bonow ML, Fleischmann MD, Mullre LT. Traumatic intrusion of primary tooth: follow up until eruption of permanent successor tooth. *Dent Traumatol* 2008;24(2):235-8.
27. Lenzi AR, Medeiros PJ. Severe sequelae of acute dental trauma in the primary dentition—a case report. *Dent Traumatol* 2006;22(6):334-6.
28. Cunha RF, Pugliesi DM, Correa MG, Assuit DM. Early treatment of an intruded primary tooth: a case report. *J Clin Pediatr Dent* 2001;25(3):199-202.

Periapical Cemental Dysplasia and an Adjacent Compound Odontoma

Gloria Lee¹, Steven R. Singer, DDS²

¹Class of 2011, College of Dental Medicine, Columbia University, NY, NY

²Columbia University, College of Dental Medicine, Division of Oral and Maxillofacial Radiology, NY, NY

Abstract

Periapical cemental dysplasia (PCD) and compound odontoma are relatively common lesions of the human jaw. PCD, a benign fibro-osseous lesion of unknown etiology, has been reported to be the most common lesion related to the formation of cementum. Compound odontoma, also of unknown etiology, accounts for the majority of odontomas—the most common odontogenic tumors in both the maxilla and mandible. Both lesions usually do not produce any symptoms and thus are typically found incidentally during routine radiographic examination. PCD and compound odontoma can share common radiographic features. However, it is rare to see both lesions simultaneously in close proximity. In this paper, we present a case of PCD and compound odontoma occurring simultaneously in the anterior mandible. We also explore the diagnostic challenges in differentiating between PCD and compound odontoma.

Introduction

As with any part of the body, a variety of lesions may occur within the mandible. Each of these lesions may have a unique origin, as well as differing clinical, radiographic and pathologic characteristics. Sometimes, radiographic imaging may not be sufficient to provide a specific diagnosis and biopsy is required. Thus, it is important to consider imaging, laboratory examinations, as well as clinical findings to arrive at the definitive diagnosis and select proper treatment.

Odontomas are the most common type of odontogenic tumor in both the maxilla and mandible. They occur from abnormal development of dental tissues due to differentiated epithelial and mesenchymal cells growing into ameloblasts and odontoblasts.¹ Odontoma is also known by the following synonyms: compound odontoma, compound composite odontoma, complex odontoma, complex composite odontoma, odontogenic hamartoma, calcified mixed odontoma, and cystic odontoma.² Presently, odontomas are classified into two types—compound and complex odontomas. Complex odontomas are most prevalent in premolar and molar regions and present as irregular radiopaque masses of amorphous calcifications surrounded by a radiolucent halo with no similarity to dental structures.^{3,4} In contrast, compound odontomas consist of multiple irregular radiopaque materials that vary in size and shape, resembling tooth-like structures called denticles.⁴ Compound odontomas are twice as common as the complex odontomas. When examined under the microscope, both

types of odontomas contain enamel, dentin, cementum, and pulp tissues.

Odontomas are usually slow-growing and painless. Since they are asymptomatic, they are usually discovered incidentally when the patient presents for routine dental care and radiographic examination. Pathologically, odontomas have been associated with trauma in primary teeth, inflammation, infection, hereditary anomalies such as Gardner's syndrome and Hermann's syndrome, odontoblastic hyperactivity, and genetic mutations.⁴ There is no gender predilection associated with odontomas. Odontomas can occur before or after the eruption of the associated tooth, and can cause impaction, delayed eruption of permanent teeth, or retention of primary teeth. However, it is very rare for a primary tooth to be associated with odontoma. Patients may be diagnosed with odontomas because the characteristic signs are observed or they present for a routine examination. Most odontomas are diagnosed in the second decade of life.³ If there is a disturbance in eruption of the tooth associated with the odontoma, then treatment, consisting of surgical removal followed by microscopic examination to confirm the diagnosis, should be rendered. If there is no effect of the odontoma on the surrounding dental structures, then no treatment is indicated.

PCD is a solid benign non-odontogenic osseous lesion of the anterior mandible.⁷ It has also had many synonyms: cementoma, fibrocementoma, sclerosing cementoma, periapical osteofibrosis, periapical fibrous dysplasia, and periapical fibroosteoma.² PCD is classified under the group of fibro-osseous lesions, with the other members of the group being focal cemento-osseous dysplasia and florid cemento-osseous dysplasia.^{6,12} PCD is localized in the mandibular anterior region. When the lesion involves diffuse areas of the mandible, at two or more quadrants, it is called florid cemento-osseous dysplasia. Florid cement-osseous dysplasia may appear similar to Paget's disease or chronic diffuse sclerosing osteomyelitis on the radiographs.⁶

PCD occurs from the proliferation of fibrous connective tissue and cementum-like hard tissues in the periodontal membrane, progressively replaces apical bone, and attenuates the lamina dura. Therefore, in the earliest phase of developing PCD (Stage I, or the "osteolytic" phase), the lesion shows radiolucency on the radiograph and is often indistinguishable from apical rarefying osteitis. Pulp vitality testing is necessary to distinguish the early lesions of PCD from

Periapical Cemental Dysplasia and an Adjacent Compound Odontoma

apical rarefying osteitis. In Stage II, or the “cementoblastic” phase, cementum or bone is deposited in the center of the lesion. Radiographically, the lesion has both radiopacity and radiolucency during this stage. In Stage III, or the “mature inactive” phase, the lesion presents as a radiopaque mass with a radiolucent periphery.⁵

PCD occurs mostly in females of African or Asian descent during the fourth and fifth decades of life.⁷ The teeth associated with the PCD usually are vital in electrical and thermal pulp tests, and these lesions do not involve inflammation.⁹ With PCD, the patient rarely has symptoms, so the lesion is usually detected and diagnosed upon routine dental care. The case is similar for odontoma. Since PCD is asymptomatic, no treatment is routinely indicated. However if the lesion is diffuse, such as in florid cemento-osseous dysplasia, treatment involved may include esthetic recontouring of the affected bone. However, this is rare.

Case Report

The patient is a 53 year old African-American female who presented to the clinic for routine dental care. Extraoral findings were unremarkable. Intraorally, non-contributory findings include missing teeth, existing restorations, and inflammation of the marginal gingiva. A full mouth series of radiographs was prescribed. Radiographic findings included missing and malposed teeth, metallic and composite restorations, and marginal periodontitis. Incidental radiographic findings of two separate mixed density lesions in the anterior mandible were noted.

Based on their radiographic appearances and patient information, the lesions were diagnosed as Stage II periapical cemental dysplasia and compound odontoma. No treatment was prescribed for the lesions and radiographic follow-up was suggested.

Discussion

Compound odontomas occur commonly in the anterior regions of the jaw. While radiographic diagnosis is often adequate, odontomas that have been removed are routinely examined histopathologically. Similarly, with PCD, a common lesion in women of African or Asian descent, surgical intervention is generally contraindicated. As with odontomas, radiographic diagnosis usually suffices, and radiographic follow-up is adequate. In fact, surgical intervention is contraindicated due to the increased risk for developing an osteomyelitis in the surrounding bone.

Radiographically, both Stage II PCD and compound odontoma present as mixed density lesions. Typically, there is a defined opacity that is surrounded by a radiolucent rim. Odontomas demonstrate a corticated border. PCD may also demonstrate a similar border, but it may be slightly

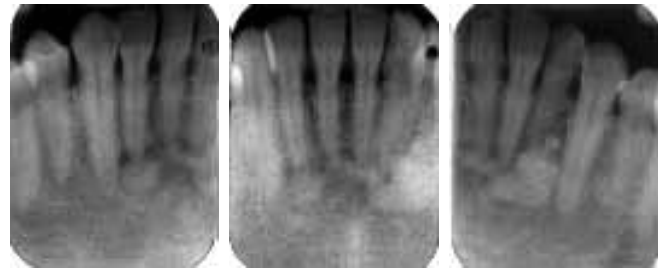


Figure 1 Periapical radiographs of the lower incisor region demonstrating lesions of periapical cemental dysplasia (white arrow) adjacent to the compound odontoma (black arrow). Note that left primary canine was retained due to odontoma

less well-defined. Upon close examination, a compound odontoma will often show a denticle or a series of denticles where the components of teeth can be distinguished. Occasionally, denticles cannot be easily differentiated. The internal opacities of PCD will be uniformly opaque, without distinct tooth-like structures.

Complex odontomas have the same degree of histodifferentiation but a lesser degree of morphodifferentiation. Unlike compound odontomas, complex odontomas are usually located in the posterior jaw, specifically in the premolar and molar areas of the mandible, and are increasingly observed in children and adolescents.^{3,4} Whereas compound odontomas are limited in their growth potential, complex odontomas occasionally demonstrate enormous growth and reach several centimeters in size.^{8,14}

Odontomas are generally intrabony lesions that are usually asymptomatic and do not affect the surrounding dental structures if they are not disturbing eruption of a nearby tooth. Yet, an exceptional situation involving odontoma is the spontaneous eruption of the odontoma itself. When odontomas erupt through the mucosal surfaces into the oral cavity, they cause pain, inflammation, and infection. It has also been reported that swelling, tongue irritation, facial asymmetry, halitosis, malocclusions, and recurrent infections have been associated with erupted odontomas.⁸ A case reported by Ferrer et al. indicated that multiple infection episodes, malaise, pain, fever, inflammation, and suppuration have been associated with the erupted odontoma. The treatment delivered for the patient was broad spectrum antibiotic treatment of the infection consisting of amoxicillin, clavulanic acid, and clindamycin, followed by surgical removal of the erupted odontoma, after which the signs and symptoms had consequently resolved.¹⁰

Another exceptional situation involving odontoma is its association with a primary tooth. Odontoma is rare in primary dentition. It is of interest to note that odontoma is the most common factor that causes tooth impaction, yet tooth impaction usually involves permanent teeth and rarely primary teeth, especially anterior primary teeth.¹ Nevertheless, there

Periapical Cemental Dysplasia and an Adjacent Compound Odontoma

have been a few reports of odontomas associated with unerupted primary teeth. In these cases, odontomas were observed periapical to, coronal to, or between the roots or crowns of primary molars, causing impaction of primary or permanent teeth.¹¹ It is important to examine the radiographs carefully, since odontomas in primary dentition are less calcified and thus slightly more radiolucent than those in the permanent dentition.¹ Treatment for such odontomas is surgical removal without disturbing the associated tooth germs to allow eruption of the impacted teeth spontaneously or with orthodontic therapy.¹¹ If eruption is not expected, then the treatment of choice is extraction.¹

PCD is characterized by usually being an asymptomatic lesion located in mandibular anterior region and occurring during the fourth and fifth decades of life in African-American or Asian women. Yet, PCD can occur and behave in a non-characteristic or unexpected way. According to Tanaka *et al*, there is a general trend of PCD occurring in the premolar and molar regions in the Japanese ethnic group.⁹ This is clearly contrary to the location of PCD in other ethnic groups—the apices of mandibular incisors. In a case report, Stoneman *et al* presents a case in which PCD was misdiagnosed as a solitary bone cyst because the patient was a girl who was only fourteen years old, much younger than the average age of PCD diagnosis. Misled by the age of the patient, dental care providers often fail to recognize and correctly interpret the radiopacities scattered throughout the radiolucency as PCD. Misdiagnosis can eventually lead to unnecessary surgical treatment.⁵

In conclusion, although there are many studies and statistical data on lesions available, diagnosis should not be restricted by epidemiological characteristics. Instead, it is important to account all clinical, radiographic, and pathologic signs and symptoms as well as differential diagnoses in order to arrive at a definitive diagnosis. Additionally, it is clear that lesions often behave in unforeseen or unusual ways. Thus, even for lesions that may not require treatments, such as compound odontoma and PCD, follow-up with routine radiographic examination is important. Correct diagnosis based on careful imaging, clinical observations, and appropriate follow-up constitutes appropriate patient management. Careful observation of the radiographic features of each lesion helps to differentiate between adjacent and unrelated lesions.

References

1. Yildirim-Oz G, Tosun G, Kiziloglu D, Durmus E, Sener Y (2007) An Unusual Association of Odontomas with Primary Teeth. *Eur J Dent* 1: 45-49.
2. White S, Pharoah M (2004). *Oral Radiology: Principles and Interpretation*. St. Louis, Mosby.
3. Hidalgo-Sanchez O, Leco-Berrocal MI, Martinez-Gonzalez JM (2008) Metaanalysis of the epidemiology and clinical manifestations of odontomas. *Med Oral Patol Oral Cir Bucal* 13(11): E730-E734.
4. Amado-Cuesta S, Gargallo-Aliol J, Berini-Aytes L, Gay-Escoda C (2003) Review of 61 cases of odontoma. Presentation of an erupted complex odontoma. *Med Oral* 8: 366-373.
5. Stoneman DW, Van de Mark TB (1974) Periapical osteofibrosis in a 14-year-old girl. *Oral Surg* 37(4): 649-652.
6. Goncalves M, Pispico R, Alves FA, Lugao CEB, Goncalves A (2005) Clinical, Radiographic, Biochemical and Histological Findings of Florid Cemento-Osseous Dysplasia and Report of a Case. *Braz Dent J* 16(3): 247-350.
7. Dunfee BL, Sakai O, Pistey R, Gohel A (2006) Radiologic and Pathologic Characteristics of Benign and Malignant Lesions of the Mandible. *RadioGraphics* 26(6): 1751-1768.
8. Serra-Serra G, Berini-Aytes L, Gay-Escoda C (2009) Erupted odontomas: A report of three cases and review of the literature. *Med Oral Patol Oral Cir Bucal* 14(6): E299-E303.
9. Tanaka H, Yoshimoto A, Toyama Y, Iwase T, Hayasaka N, Moro I (1987) Periapical cemental dysplasia with multiple lesions. *Int J Oral Maxillofac Surg* 16: 757-763.
10. Ferrer M, Silvestre F, Estelles E, Grau D (2001) Infección recurrente de un odontoma complejo tras su apertura a la boca. *Med Oral* 6:269-275.
11. Teruhisa U, Murakami J, Hisatomi M, Yanagi Y, Asaumi J (2009) A Case of Unerupted Lower Primary Second Molar Associated with Compound Odontoma. *The Open Dentistry Journal* 3: 173-176.
12. Matsuzaka K, Shimono M, Uchiyama T, Noma H, Inoue T (2002) Lesions related to the formation of bone, cartilage or cementum arising in the oral area: A statistical study and review of the literature. *Bull Tokyo Dent Coll* 43(3): 173-180.
13. Smeele LE, Baart JA, Van der Waal I (1991) Unusual behavior of periapical cementous dysplasia. *British Journal of Oral and Maxillofacial Surgery* 29: 58-60.
14. Singer SR, Mupparapu M, Milles MM, Rinaggio J, Pisano D, Quaranta P (2007) An unusually large complex odontoma in the maxillary sinus associated with an unerupted tooth. Report of a case and review of literature. *NYS Dent J*. 73(4): 51-53.

Management of Tooth Agenesis by Orthodontic Space Closure: A Case Study

Grace Sun Ae Hur¹, Jin Kim, DDS, MS², Jenny Zhu, DDS, MS³, Ülkü Z. Ersoy, DDS, DMSc⁴

¹Class of 2012, College of Dental Medicine, Columbia University, New York, NY

²Former Columbia postgraduate orthodontic student; private practice, San Antonio, TX

³Former Columbia postgraduate orthodontic student; private practice, New York, NY

⁴Assistant Professor, Division of Orthodontics, College of Dental Medicine, Columbia University, New York, NY

Abstract

Tooth agenesis is a developmental defect characterized by the absence of one or more teeth in either the primary or permanent dentition. Customary treatment options include orthodontic space closure of the edentulous area, tooth-supported restorations and single-tooth implants, all of which have advantages and disadvantages. This article aims to discuss the benefits of orthodontic space closure when compared to the other two above-mentioned alternatives.

Introduction

Hypodontia refers to the developmental absence of one or more teeth, oligodontia of six or more teeth, and anodontia of all teeth. The prevalence of hypodontia in primary dentition varies from 0.08% to 1.55%, with no gender predilection. In the permanent dentition, the prevalence is higher, ranging from 2.3% to 11.3%, and females are more frequently affected than males by a ratio of 3:2.5. The prevalence of missing third molars is between 9% and 37%, making this the most frequently absent tooth in the permanent dentition. It is generally agreed that mandibular second premolars are the next most commonly missing tooth, followed by maxillary lateral incisors, maxillary second premolars, and finally, mandibular central incisors. One or two of these teeth are absent in 80% of reported cases, 4 or more in 10%, and 6 or more in fewer than 1%.¹ Interestingly, maxillary lateral incisors are the most frequently missing teeth when only one or two teeth are missing, while second premolars are most frequently missing when more than two teeth are missing.²

Terminology regarding this subject warrants its own discussion. Vastardis³ identifies the ubiquitous term “congenitally” missing teeth as a misnomer, since those permanent teeth that are most often missing are not always present at birth in normal development. Tooth agenesis is a more descriptive term that indicates an underlying developmental defect. The recent approach to understanding dental anomalies reflects this ideology, and human molecular genetics has allowed recognition of specific genes that are responsible for tooth agenesis in certain families. Tucker and Sharpe⁴ discuss the association between non-syndromic tooth agenesis and heterozygous mutations in transcription factors *Msx1* and *Pax9*, which have been shown to play a critical role in the early stages of tooth development.

The treatment options for tooth agenesis are as varied as the types and number of teeth missing in the condition. Current research has attempted to bioengineer teeth either from existing dental cells or progenitor tissues, based on the knowledge of the interaction between mesenchyme and epithelium to replicate the natural process. The results have been largely encouraging: enamel, dentin, pulp, and developing tooth roots have been regenerated on prefabricated biodegradable scaffolds.⁵

Still, a wide gap exists between what are still the initial stages of tissue bioengineering research and the therapies available today to treat hypodontia. Three of the more common treatments involve orthodontic space closure of the edentulous area, tooth-supported restorations, and single-tooth implants. Beyond their challenges and benefits, the choice of treatment is further complicated by factors such as the type of malocclusion, space requirements, tooth size relationships, and the size and shape of the canine in cases where the maxillary lateral incisor is missing.⁶

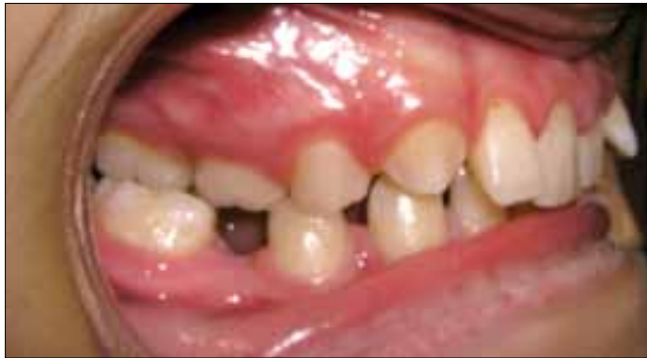When the closure of the edentulous space is indicated, the orthodontist uses brackets and arch wires to bring the adjacent teeth into contact. However, when the missing tooth is located in the anterior maxilla, where esthetics is a major concern, additional steps are required. For example, when the canine substitutes a congenitally missing lateral incisor, the canine must be reduced incisally, palatally and labially prior to proper positioning, and possibly restored at the mesioincisal and distoincisal edges. Moreover, the tendency of the canine to have a darker color than the contralateral lateral incisor must be offset by individual bleaching. Esthetics may be further fine-tuned via gingivectomy to mimic natural gingival margin contours.⁶

In contrast to orthodontic space closure, most tooth-supported restorations require a prior opening of space to regain the width lost from ectopic eruption of the canine into the lateral incisor location. Three different methods exist that determine the appropriate space: the “golden proportion” rule, which states that the apparent width of anterior teeth should have a ratio of 1:0.618 with adjacent teeth from the frontal view, the use of the contralateral lateral incisor as a guide for space determination, or the use of the Bolton ratio

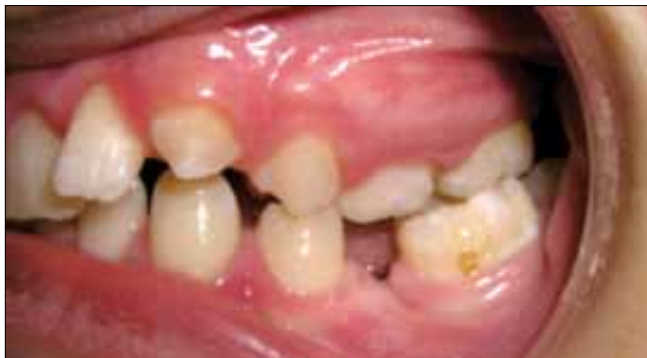Management of Tooth Agenesis by Orthodontic Space Closure: A Case Study

to compare the mesiodistal widths of individual teeth in the opposing arches to obtain an ideal occlusal relationship.⁷ Implant-supported restorations have become a popular treatment modality for missing teeth. The purpose of orthodontic space opening in this option is two-fold: the space for the implant-abutted crown is acquired, and the significant buccolingual width of the canine widens the edentulous ridge to accommodate proper implant placement. This width is stable over time, such that the implant can be placed after facial growth is complete.⁸

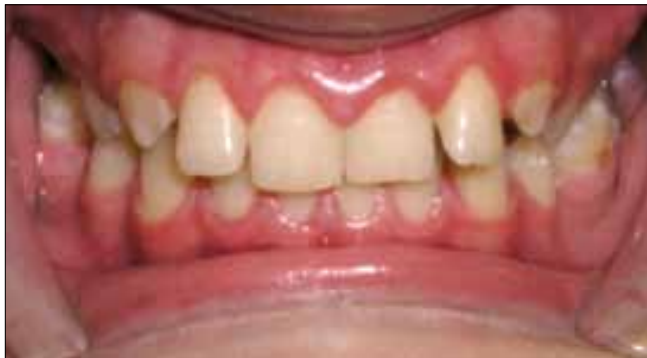Figure 1A Initial intraoral photographs



Right view



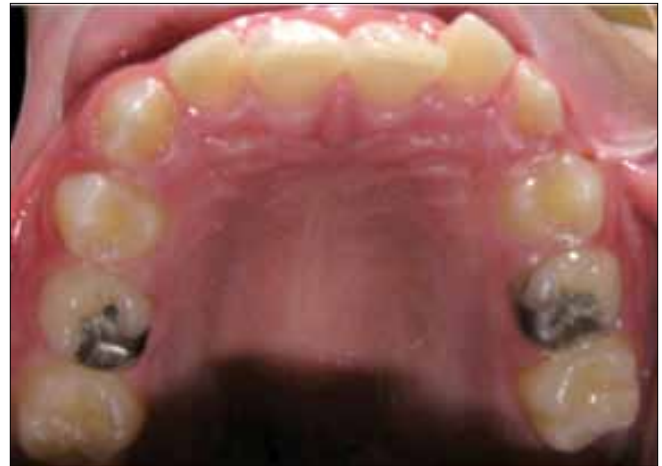Left view



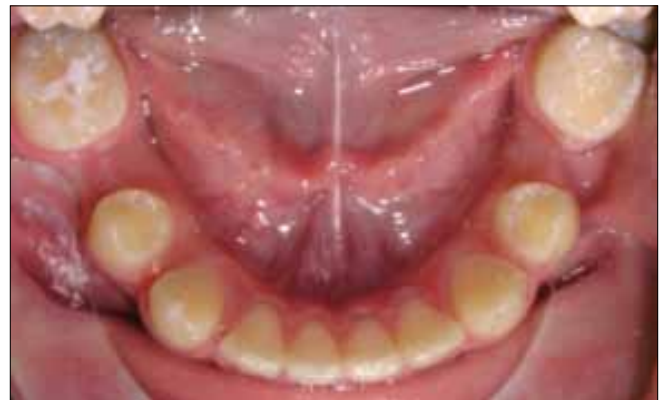Frontal view

Case Report

An 11-year 2-month old male with congenital agenesis of both mandibular second premolars presented for orthodontic treatment at the Columbia University Post-Doctoral Orthodontic Clinic. The patient's chief complaint was "my front teeth are not lined up with the other teeth." Clinical exam and study models revealed an Angle Class III (Subdivision left) occlusion, Class II canine relationship, bilateral posterior molar crossbite, 6 mm overjet, deep overbite, mildly misaligned maxillary teeth, and an atrophic dentoalveolar ridge where the mandibular second premolars were missing (*Figure 1*).

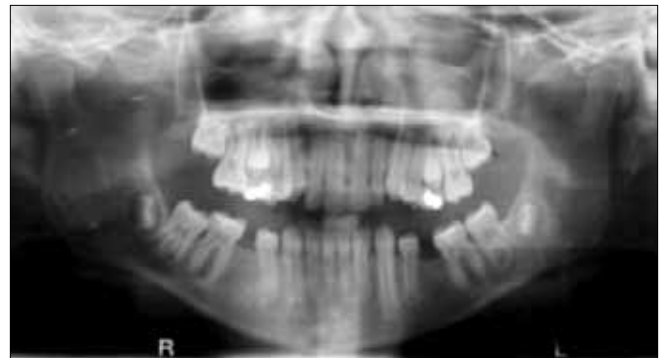

Occlusal view (maxillary)



Occlusal view (mandibular)

Figure 1B Initial panoramic radiograph



Management of Tooth Agenesis by Orthodontic Space Closure: A Case Study

A measure of the patient's TMJ function resulted in a maximum opening of 45 mm and maximum protrusion of 7 mm. A functional shift to the right of 3 mm was observed, and lateral movements were 7 mm to the right and 5 mm to the left. The patient reported no discomfort, pain, spasms, clicking, or noise in his jaw joints.

Cephalometric analysis revealed a Skeletal Class I tendency, a hypodivergent mandibular angle, slightly retroclined and retruded lower incisors, an obtuse interincisal angle, a prominent chin, and a slight skeletal and soft tissue imbalance (*Figure 2*).

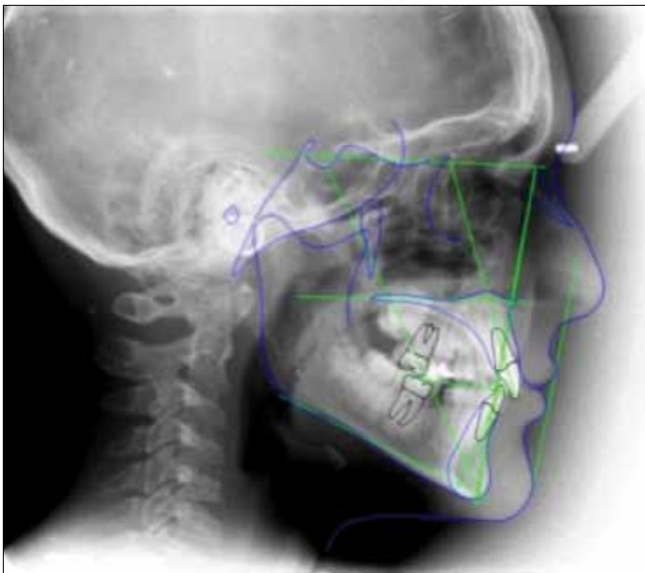


Figure 2A Initial digitized lateral cephalogram

Figure 2B Initial Columbia Analysis

	Value	Norm	SD	Dev Norm
SNA (°)	81.1	81.0	4.0	0.0
SNB (°)	80.8	78.0	3.0	0.9
ANB (°)	0.3	3.0	2.5	-1.1 *
Wits Appraisal (mm)	1.8	1.0	3.0	0.3
SN - GoGn (°)	26.6	32.0	5.0	-1.1 *
SN-Palatal (SN-PP) (°)	3.2	8.2	3.3	-1.5 *
Palatal-Mand Angle (PP-GoGn) (°)	23.4	22.0	6.0	0.2
Y-Axis (SGn-SN) (°)	65.1	67.0	5.5	-0.3
P-A Face Height (S-Go/N-Me) (%)	68.1	65.0	4.0	0.8
UAFH/LAFH Ratio (N-ANS/ANS-Me) (%)	75.0	80.0	7.0	-0.7
U1 - SN (°)	107.3	103.5	5.0	0.8
Interincisal Angle (U1-L1) (°)	137.0	130.0	5.0	1.4 *
L1 - GoGn (°)	89.1	93.0	6.0	-0.7
L1 Protrusion (L1-APo) (mm)	0.7	1.0	2.0	-0.2
L1 - NB (mm)	2.0	4.0	1.8	-1.1 *
Pog - NB (mm)	2.6	4.0	1.5	-0.9
Holdaway Angle (NB to H-line) (°)	2.0	8.0	4.0	-1.5 *
Holdaway Ratio (L1-NB:Pg-NB) (%)	0.8	1.0	1.0	-0.2

Full comprehensive treatment with the Edgewise appliance was elected with the patient's consent. In the spring of 2004, the Haas Expander was first used to correct the transverse discrepancy; this rapid palatal expander was bonded to upper 4's and 6's and turned twice a day for a duration of six weeks. Although expansion was discontinued at this point, the appliance was maintained intraorally for the purpose of retention. One month after the expansion was terminated, brackets were bonded to individual teeth.

Because the patient did not wish to receive dental implants to restore the missing mandibular second premolars, the treatment objectives included the planned closing of the edentulous space via orthodontic forces. They also included improving oral hygiene, achieving Class I canine relationship, closing all spaces, correcting the deep bite and crossbite, leveling and aligning, correcting dental rotations, improving the interincisal angle, improving the lower incisal angle, and monitoring lower third molar eruption.

The Sabbagh Universal Spring (SUS) was fitted approximately one month prior to placement of the rapid palatal

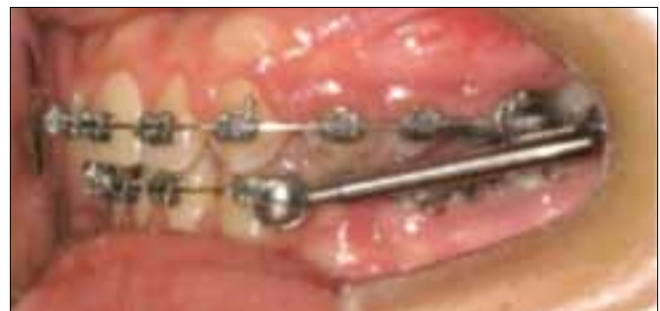
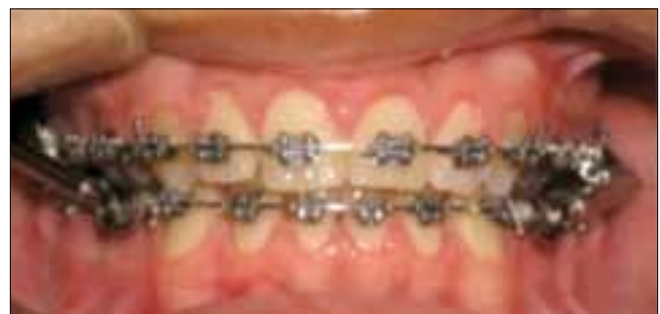
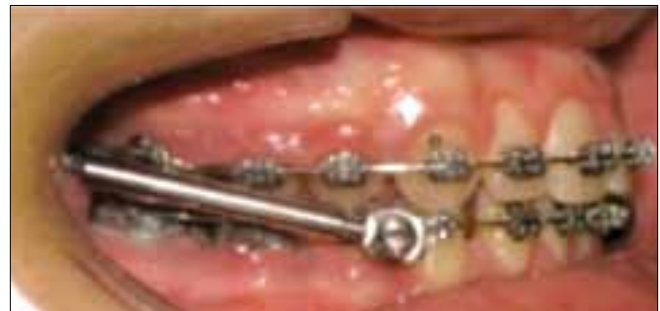Figure 3 Intraoral photographs with the Sabbagh Universal Spring

Management of Tooth Agenesis by Orthodontic Space Closure: A Case Study

expander; its purpose was to enhance the mandibular anterior anchorage while closing the spaces between mandibular first premolars and first molars. This appliance (Figure 3) is a telescope unit with a spring for universal intermaxillary use. It produces constant, mainly horizontal forces when the mouth is closed. The SUS is gentle on the temporomandibular joints and is ideal for patient with poor cooperation. The SUS is commonly used for molar distalization, space closure, dentoalveolar compensation of the occlusion, and temporomandibular dysfunction.⁹

The main concern with orthodontic space closure involves the health of the periodontium surrounding the first premolars and first molars. Periapical radiographs taken on January 14 of 2008 showed no loss in vertical height of bone (Figure 4). Probing depth measurements taken on the same day were also within an acceptable range (Table 1).

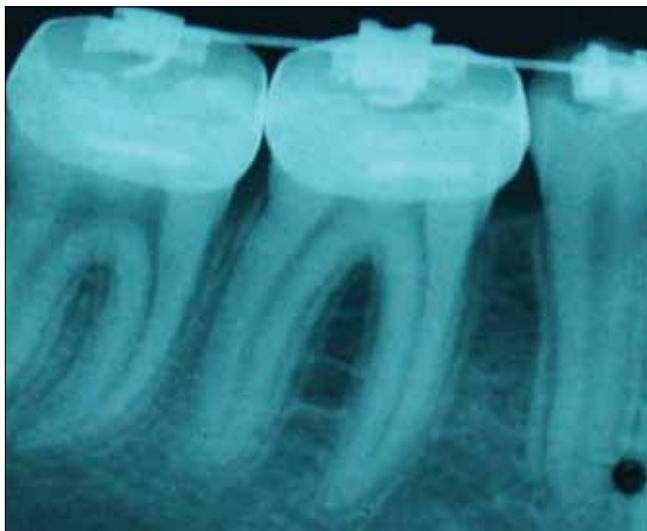

Figure 4
Periapical radiographs of the mandibular first molars after space closure

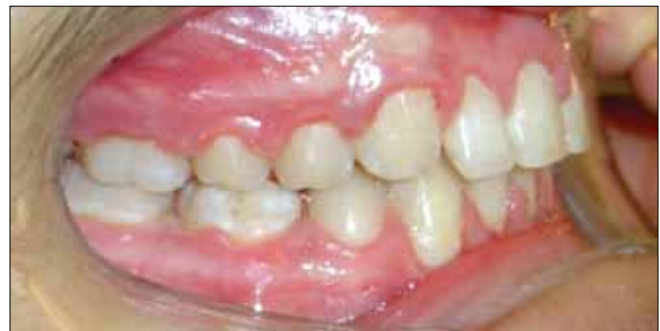Table 1
Probing depths of mandibular first premolars and first molars
D-Distal, L-Lingual, M-Mesial, B-Buccal

	DL	L	ML	MB	B	DB
Right first molar	4	4	4	4	3	5
Right first premolar	3	2	2	3	3	3
Left first premolar	3	3	3	2	2	2
Left first molar	4	4	3	3	3	4

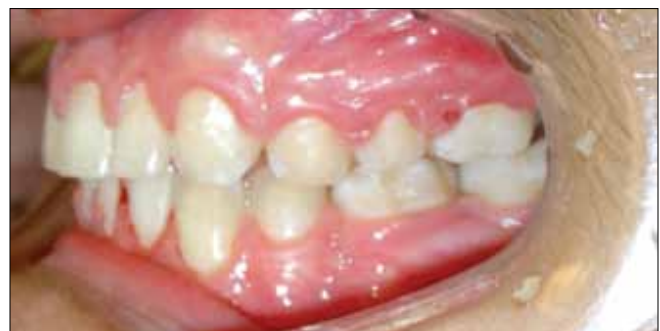Although the distals of first molars had deeper measurements, the inflammation is more likely due to molar bands that inhibit better hygiene. The patient's brackets were removed on July 2 of 2008, totaling approximately four years and one month of treatment.

Final records were taken on October 20 of 2008. Clinical exam exhibited complete closure of the edentulous spaces by mesialization of mandibular molars, Angle Class III occlusion, Class I canine relationship, correction of bilateral posterior molar crossbite, and ideal overjet and overbite. Meanwhile, the panoramic radiograph confirmed alignment of both crowns and roots (Figure 5).

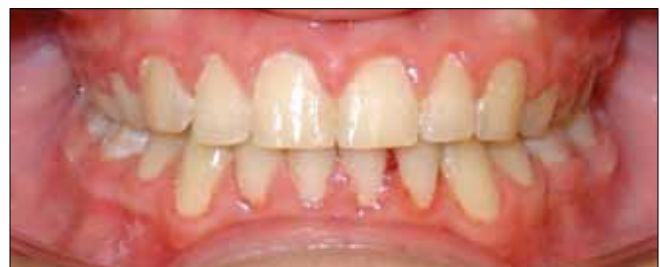Figure 5A Final intraoral photographs



Right view



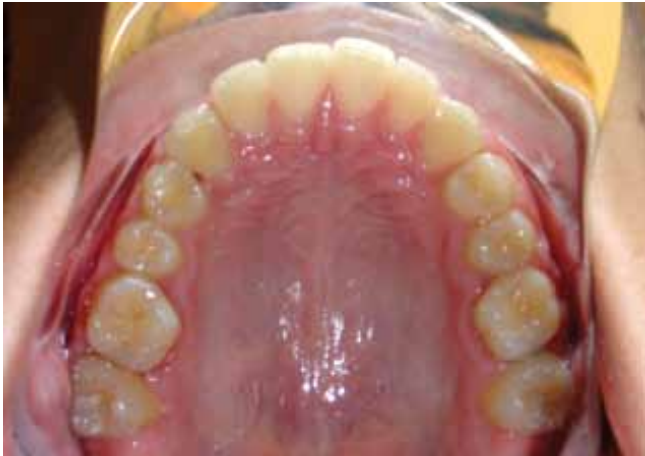Left view



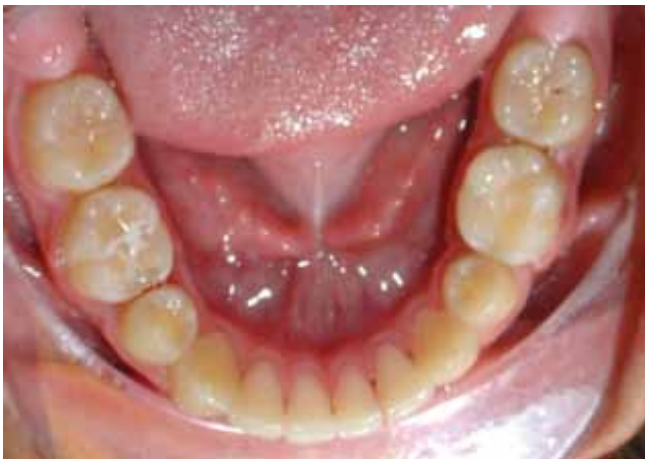Front view

Management of Tooth Agenesis by Orthodontic Space Closure: A Case Study

Figure 5A (continued) Final intraoral photographs

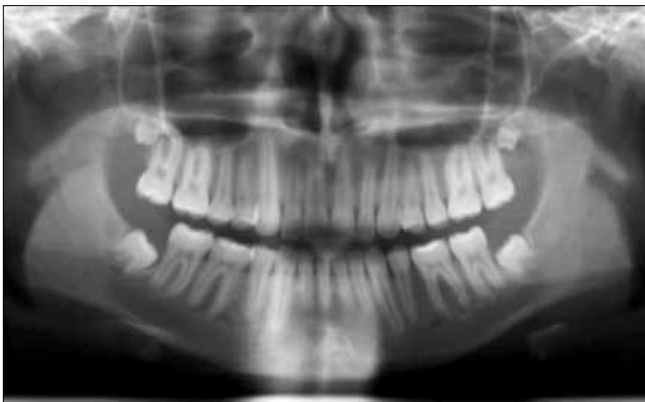

Occlusal view (maxillary)



Occlusal view (mandibular)

Figure 5B Final panoramic radiograph



Cephalometric analysis demonstrated improvement in the interincisal angle as compared to pre-treatment, which was partly due to the mechanics increasing the lower incisor inclination. The patient remained in a hypodivergent skeletal vertical pattern, because of growth and/or space closure orthodontic mechanics. Overall, the patient's natural profile was maintained and a stable dental correction resulted (Figure 6).

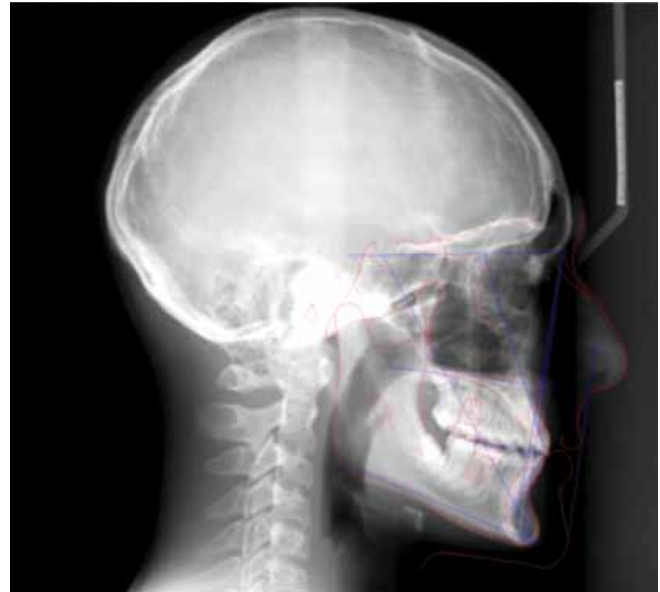

Figure 6A Final digitized lateral cephalogram

	Value	Norm	SD	Dev Norm
SNA (°)	79.4	81.0	4.0	-0.4
SNB (°)	81.2	78.0	3.0	1.1 *
ANB (°)	-1.8	3.0	2.5	-1.9 *
Wits Appraisal (mm)	-3.9	1.0	3.0	-1.6 *
SN - GoGn (°)	23.3	32.0	5.0	-1.7 *
SN-Palatal (SN-PP) (°)	7.6	8.2	3.3	-0.2
Palatal-Mand Angle (PP-GoGn) (°)	15.7	22.0	6.0	-1.1 *
Y-Axis (SGn-SN) (°)	63.6	67.0	5.5	-0.6
P-A Face Height (S-Go/N-Me) (%)	70.7	65.0	4.0	1.4 *
UAFH/LAFH Ratio (N-ANS/ANS-Me) (%)	83.0	80.0	7.0	0.4
U1 - SN (°)	106.2	103.5	5.0	0.5
Interincisal Angle (U1-L1) (°)	131.0	130.0	5.0	0.2
L1 - GoGn (°)	99.5	93.0	6.0	1.1 *
L1 Protrusion (L1-APo) (mm)	2.3	1.0	2.0	0.7
L1 - NB (mm)	3.7	4.0	1.8	-0.2
Pog - NB (mm)	5.8	4.0	1.5	1.2 *
Holdaway Angle (NB to H-line) (°)	-0.1	8.0	4.0	-2.0 **
Holdaway Ratio (L1-NB:Pg-NB) (%)	0.6	1.0	1.0	-0.4

Figure 6B Final digitized Columbia Analysis

In addition, because the third molars were developing at this time, a follow-up panoramic radiograph was taken on February 16 of 2010 to examine the eruption path (Figure 7). This image, along with the clinical exam, showed that the mandibular third molars were erupting into proper position and would occlude with the maxillary second molars.

Discussion

With the advent of new treatment modalities, the patient is often faced with numerous choices that sometimes can be difficult to navigate. In the case of tooth agenesis, three

Management of Tooth Agenesis by Orthodontic Space Closure: A Case Study

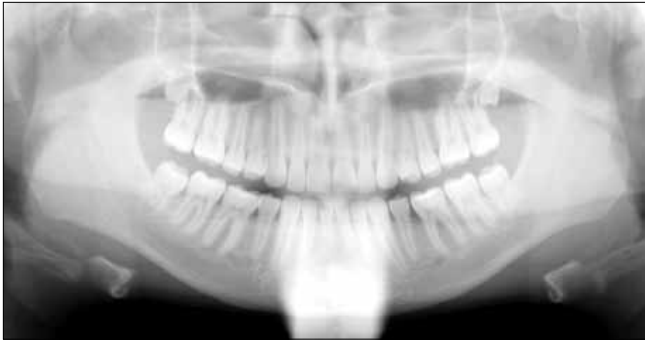

Figure 7 Follow-up panoramic radiograph

widespread alternatives to tissue regeneration therapy include orthodontic space closure, a tooth-abutted bridge, or an implant-supported crown. Although these treatment options are clear enough, the choice of treatment involves many factors that complicate the decision-making process.

Carter *et al*¹⁰ explains that three factors determine whether to maintain an edentulous space or to close it: the age of the patient, the severity of the hypodontia, and the degree of inherent crowding. Younger patients benefit from facial and dentoalveolar growth, such that astute extraction of primary teeth in mildly crowded cases may guide the permanent teeth into more favorable eruption positions. Additionally, space closure seems less likely as the number of missing teeth increases, and as crowding of the arch decreases.

Thilander¹¹ elaborates on age as a factor by stating that whereas orthodontic space closure guides the erupting teeth into stable occlusion in children, interlocking intercuspation requires an extenuating treatment in the opposite arch in adolescents and young adults. In the latter case, tipping of teeth is precluded with bodily orthodontic movements that are light in force to avoid destruction of gingiva and marginal bone loss. These mechanics require such a significant time commitment that the alternative choice of an implant should be considered.

Closing the edentulous space by orthodontic means is clearly favored in growing children, but adolescents and young adults may benefit from other treatment alternatives. Still, tooth-supported restorations and single-tooth implant are not without shortcomings. Tooth-supported restorations — that is, conventional full-coverage fixed partial dentures require not only preparation, but precise planning as well. In cases where orthodontic therapy is planned, the anticipated abutment teeth should be aligned along a common pathway so that the amount of tooth structure prepared is minimal; this prevents weakening of the abutment and pulpal encroachment. Clearly, the non-conservative nature of this treatment is not ideal for restoring an anterior tooth such as the maxillary lateral incisor.⁷

Careful planning also applies to implant-supported crowns that replace missing teeth. Implant fixtures cannot be placed in any edentulous space; rather, certain specifications exist. For instance, the minimum interradicular distance is 5 mm, and 1.5 to 2.0 mm of space between head of the implant and adjacent teeth is essential for development of the papillae. As a result, while coronal space may be adequate, insufficient interradicular spacing may limit implant placement as a restorative option.⁸

Treatment time is of concern as well. Facial growth and tooth eruption must be complete before placement of the implant fixture can occur.^{2,8,12} This requirement delays the continuity of the restoration, prolonging the overall time span that the patient is receiving therapy. Because the length of time to implant placement varies, the more definitive treatment time for orthodontic space closure may become more attractive. The patient in the case report had four years and one month of active treatment, yet waiting for growth completion might have been as long or even longer in duration.

As much as practicality sways treatment options, the final esthetic result could be considered to be of equal importance. More specifically, management of the soft tissue visible while smiling. For instance, with regard to implants replacing maxillary lateral incisors, Thilander identified several periodontal problems. Not only was mucosal recession at the crown observed, but there was also marginal bone loss that led to mucosal discoloration.¹¹ Atherton also claimed that when space is opened for a fixed partial denture or implant, teeth moving apart caused the papilla to remain in place while the adjacent sulci were everted. This became a challenge as the restoration lacked the proper emergence profile to mimic a natural tooth.⁸

On the contrary, Day *et al* noted that mesialization of the tooth posterior to the edentulous space established a new alveolar process along with attached gingiva and interdental papillae.¹³ The appearance of the soft tissue was therefore maintained, which is difficult in fixed partial dentures and implants.¹² In fact, Zeisner and Witt found no adverse periodontal effects from orthodontic space closure.¹⁴ The case report confirms this by demonstrating healthy vertical bone height with adequate amount of attached gingiva and interdental papillae surrounding the mandibular first premolars and molars. The probing depths were also within normal limits, as compared to prosthetic replacements that may harm periodontal health by causing plaque retention.

Both the Herbst appliance¹⁶ and the SUS9 bring teeth forward without requiring patient cooperation. The former corrects skeletal and dental Class II malocclusion, and is either bonded or removable. The Herbst appliance 's disadvantage is that its rigidity limits mandibular lateral excu-

Management of Tooth Agenesis by Orthodontic Space Closure: A Case Study

sions and makes it prone to breakage. However, SUS⁹ is an attractive alternative device that is well accepted by patients due to its delicate design and its slow and gentle force-delivery system. When employed for agenesis of the mandibular second premolar, the spacing is slowly closed by protracting the molars mesially into the atrophic dento-alveolar ridge. This methodology is based on the report by Kokich *et al*¹⁷ that moving the adjacent tooth into the atrophic space, if done slowly, will permit alveolar cortical bone to be deposited ahead of and around the tooth.

The SUS addresses another issue that often undermines orthodontic space closure—unintentional retraction of anterior teeth. This movement adversely affects the incisor relationship; the overjet often seen in Angle Class II occlusion is worsened.¹⁰ The SUS prevents unwanted retraction by using push-pull mechanics: closing the mouth pushes the anterior tooth bonded to the appliance mesially rather than distally into the space.

Conclusion

Patient selection is critical in treating patients with tooth agenesis. Candidates for space closure, tooth-supported restorations, and single-tooth implants all require a thorough workup that considers the age of patient, feasibility of an esthetic fixed partial denture or implant-supported crown, treatment time, and soft tissue management. In cases where orthodontic space closure is selected, the Sabbagh Universal Spring is a good alternative to traditional functional appliances.

Regardless of the treatment of choice, a team approach between the restorative dentist and periodontist is a must. Consultation during treatment planning and coordination should be multidisciplinary, while subsequent therapy should be interdisciplinary. This will allow the clinician to provide optimum care as well as maximum satisfaction for the patient.¹

References

1. McNamara C, Foley T, McNamara CM (2006) Multidisciplinary management of hypodontia in adolescents: case report. *J Can Dent Assoc* 72(8): 740-6.
2. Park JH, Okadakage S, Sato Y, Akamatsu Y, Tai K (2010) Orthodontic treatment of a congenitally missing maxillary lateral incisor. *J Esthet Restor Dent* 22: 297-313.
3. Vastardis H (2000) The genetics of human tooth agenesis: new discoveries for understanding dental anomalies. *Am J Orthod Dentofacial Orthop* 117: 650-6.
4. Nieminen P (2009) Genetic basis of tooth agenesis. *J Exp Zool* 312B: 320-342.

5. Tucker A, Sharpe P (2004) The cutting-edge of mammalian development; how the embryo makes teeth. *Nat Rev Genet* 5: 499-508.
6. De Coster PJ, Marks LA, Martens LC, Huysseune A (2009) Dental agenesis: genetic and clinical perspectives. *J Oral Pathol Med* 38: 1-17.
7. Thesleff I (2006) The genetic basis of tooth development and dental defects. *Am J Med Genet* 140A: 2530-2535.
8. Sharpe Pt, Young CS (2005) Test-tube teeth. *SciAm* 293: 34-41.
9. Kokich VO Jr, Kinzer GA (2005) Managing congenitally missing lateral incisors. Part I: Canine substitution. *J Esthet Restor Dent* 17: 5-10.
10. Kinzer GA, Kokich VO Jr (2005) Managing congenitally missing lateral incisors. Part II: tooth-supported restorations. *J Esthet Restor Dent* 17: 76-84.
11. Kinzer GA, Kokich VO Jr (2005) Managing congenitally missing lateral incisors. Part III: single-tooth implants. *J Esthet Restor Dent* 17: 202-210.
12. <http://www.sabbagh64.com> (March 2, 2011)
13. Carter NE, Gillgrass TJ, Hobson RS, Jepson N, Meechan JG, Nohl FS, Nunn JH (2003) The interdisciplinary management of hypodontia: orthodontics. *Br Dent J* 194: 361-366.
14. Thilander B (2008) Orthodontic space closure versus implant placement in subjects with missing teeth. *J Oral Rehabil* 35 (Suppl. 1): 64-71.
15. Day PF, Kindelan SA, Spencer JR, Kindelan JD, Duggal MS (2008) Dental trauma: part 2. Managing poor prognosis anterior teeth – treatment options for the subsequent space in a growing patient. *J Orthod* 35: 143-155.
16. Czochrowska EM, Skaare AB, Stenvik A, Zachrisson BU (2003) Outcome of orthodontic space closure with a missing maxillary central incisor. *Am J Orthod Dentofacial Orthop* 123: 597-603.
17. Wriedt S, Werner P, Wehrbein H (2007) Tooth shape and color as criteria for or against orthodontic space closure in case of a missing lateral incisor. *J Orofac Orthop* 68: 47-55.
18. Robertsson S, Mohlin B (2000) The congenitally missing upper lateral incisor. A retrospective study of orthodontic space closure versus restorative treatment. *Eur J Orthod* 22: 697-710.
19. Pancherz H (1997) The effects, limitations, and long-term dentofacial adaptations to treatment with the Herbst appliance. *Semin Orthod* 4: 232-43.
20. Spear FM, Mathews DM, Kokich VG (1997) Interdisciplinary management of single-tooth implants. *Semin Orthod* 3: 45-72.

Van der Woude Syndrome: A Case Study

Justin Ohnigian¹, Kristen Lowe DDS,² Ronnette Garcia DDS, MS³

¹Class of 2012, College of Dental Medicine, Columbia University, New York, NY

²Orthodontic Resident, Division of Orthodontics, Columbia University, New York, NY

³Assistant Clinical Professor, Division of Orthodontics, Columbia University, New York, NY

Abstract

Van der Woude Syndrome (VWS) is reported in male patient B.S. (12 y, 3 m). His past surgical history includes lip repair shortly after birth and hard and soft palate repair at 1 year of age. The patient presented with a desire to improve his dental and facial esthetic appearance, stating that he, “wants to get [his] mom’s type of teeth.” This case report describes the key facts and features associated with VWS and why it is underdiagnosed, as well as the importance of early diagnosis. Also included in this review are the orthodontic diagnosis and the comprehensive orthodontic and surgical treatment plans for this patient.

Introduction

VWS is the most frequent form of syndromic clefting and accounts for approximately 2% of all cleft lip and palate cases.^{1,2} This is an inherited condition transmitted through an autosomal dominant pattern that predominantly affects facial development. Van der Woude syndrome is relatively rare, as the prevalence ranges from 1:40,000 to 1:100,000 still or live births as recorded in a study of European and Asian populations.³

This syndrome is the most common cause of cleft lip and palate resulting from variations in a single gene.³ The mutated gene associated with Van der Woude syndrome is the interferon regulatory factor-6 gene (IRF6). Mutations of this gene can lead to a spectrum of phenotypes, ranging from Van der Woude syndrome in the mildest cases to Popliteal Pterygium Syndrome (PPS), which is a more severe manifestation involving abnormal genitalia, syndactyly of the toes and/or fingers, as well as other distal limb abnormalities.⁴ Sequence analysis of the IRF6 gene has shown mutations in approximately 70% of individuals with VWS and 97% of individuals with PPS phenotypes.^{5,4}

The most common manifestation associated with VWS is congenital, usually bilateral, paramedian lower-lip fistulae (also known as lip pits) or sometimes small mounds with a sinus tract leading from a mucous gland of the lip. Other common congenital developmental abnormalities associated with this syndrome are hypodontia, cleft lip, cleft palate, or both cleft lip and palate.

Case Report

Patient BS (12y, 3m male), with previously diagnosed Van der Woude Syndrome, presented to the Columbia University College of Dental Medicine Orthodontic Post Doctoral

clinic on 12/13/2005. BS was an example of a cleft lip and palate phenotype presenting as a manifestation of VWS. It is important to note that cleft lip and palate is usually non-syndromic and presents due to multiple gene irregularities. In those cases which are derived from a syndrome, VWS has been described as the most frequent form.² He presented with a past surgical history of repaired cleft lip and palate. The cleft lip surgery and both hard and soft palate surgeries were performed by the age of 1 year. His medical history was otherwise noncontributory, and the patient presented with no other significant medical problems or known drug allergies.

Upon clinical examination, BS was in permanent dentition, had a retained primary tooth (A), and was congenitally missing teeth #4 and 10 (*Figure 1*). He had no clinical

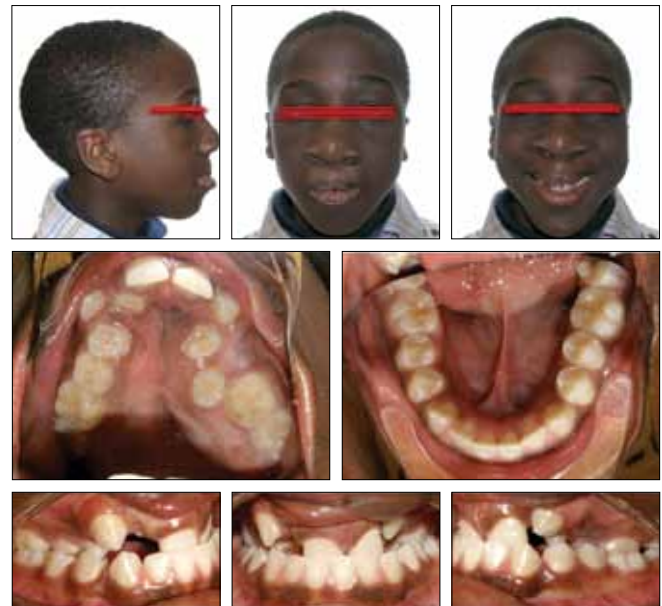


Figure 1-Initial composite photographs

Patient BS on 12/13/05. BS is 12 years and 3 months old. In the frontal view, the patient's paramedian submucous clefts (lip pits) on his lower lip are apparent photographically, and even more so clinically.

signs of caries, reported the last dental cleaning to be 3 months ago, and reported brushing two times daily. Facial examination noted this patient had mesiofacial-dolichofacial structure with marked soft tissue asymmetry, most likely as a result from cleft lip repair. This asymmetry manifested as a nose that was both larger and positioned more superiorly on the patient's right side. The patient was described as having a convex profile with a slightly prognathic maxilla and

Vander Woude Syndrome: A Case Study

a slightly retrognathic mandible. He presented with severe transverse maxillary constriction and a hyperdivergent, vertical growth pattern. There was noted class II molar occlusion with premolar crossbite on the right side and Class II molar occlusion with molar and premolar crossbite on the left side. In addition to the bilateral posterior crossbite, there was an anterior crossbite resulting in a negative overjet. This led to a negative overjet recorded at 2mm with a deep overbite. The maxillary midline was 2 mm to the left and the mandibular midline was 2 mm to the right.

Radiographs taken included a lateral cephalogram (Figure 2A), a panoramic film, and a hand/wrist film. Columbia Analysis (Figure 2B) was used to make several different recordings on the lateral cephalograph to help with diagnosis and treatment planning. In a 12-year-old male, it was very important to assess the indicators that helped determine the patient's direction of growth. Lateral cephalograph readings showed an SN-SN-GoGn angle of 44.8°, and a large Y-axis (SGn-SN) of 78.3°, both of which indicate a hyperdivergent and unfavorable vertical growth pattern. ANB was recorded at 9.2°, which describes a maxillary and mandibular disharmony suggesting a skeletal class II malocclusion. Additionally, the patient was described as having a small posterior to anterior face height ratio, which further supported the conclusion that this patient exhibited a high mandibular plane angle with unfavorable growth. Other significant anomalies that needed to be addressed included severely retroinclined maxillary incisors and protrusive mandibular incisors, both of which contributed to the negative overjet described above.

Impressions were taken and processed into the OrthoCAD digital system (Cadent Inc.) for analysis. Bolton Analysis was used to describe tooth size discrepancies between the upper and lower dental arches. This analysis, useful for permanent dentition only, described an overall mandibular excess of 4.1 mm and an anterior mandibular excess of 3.5 mm. The maxilla was seen to have 5.5 mm of crowding when missing teeth number # 4, 7 (which was extracted), and # 10 were taken into account.

The skeletal maturation index (SMI) was used to determine the amount of skeletal growth completed and amount of skeletal growth that the patient will still undergo. The patient's hand-wrist radiograph indicated ossification of the adductor sesamoid bone in the thumb without capping of the distal phalanx on the third finger. This assessment suggested BS to be at a skeletal maturation index of 4. His S-A growth was 20.3% complete and S-Gn growth was 26.7% complete, indicating that BS still had a considerable amount of growth potential remaining.⁶

Orthodontic treatment objectives for this patient were to:

Figure 2a and 2b Initial Lateral Cephalogram tracing and Columbia Analysis measurements.

Figure 2A

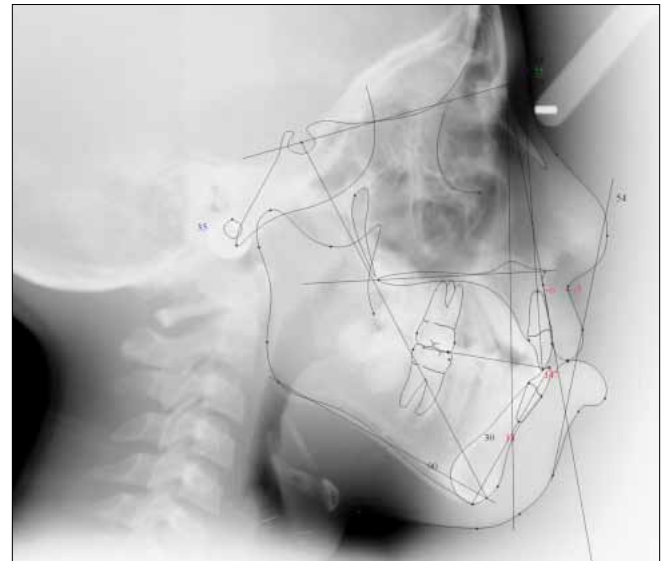


Figure 2B

Group/ Measurement	Value	Norm	Std Dev	Dev Norm
SNA (°)	84.4	81.0	4.0	0.8
SNB (°)	75.2	78.0	3.0	-0.9
ANB (°)	9.2	3.0	2.5	2.5**
Wits Appraisal (mm)	1.5	1.0	3.0	0.2
SN-GoGn (°)	44.8	32.0	5.0	2.6**
SN-Palatal (SN-PP) (°)	12.6	8.2	3.3	1.3*
Palatal-Mand Angle (PP-GoGn) (°)	32.2	22.0	6.0	1.7*
Y-Axis (SGn-SN) (°)	78.3	67.0	5.5	2.0**
P-A Face Height (S-Go/N-Me) (%)	56.2	65.0	5.5	-2.2**
UAFH/LAFH Ratio (%) (N-ANS/ANS-Me)	77.9	80.0	7.0	-0.3
U1-SN (°)	78.2	103.5	5.0	-5.1*****
Interincisal angle (U1-L1) (°)	146.8	130.0	5.0	3.4***
L1-GoGn (°)	90.2	93.0	6.0	-0.5
L1 Protrusion (L1-APo) (mm)	8.0	1.0	2.0	3.5***
L1 -NB (mm)	12.4	4.0	1.8	4.7*****
Pog-NB (mm)	-5.2	4.0	1.5	-6.1*****
Holdaway Angle (NB to H-line) (°)	12.3	8.0	4.0	1.1*
Holdaway Ratio (L1-NB:Pg-NB) (%)	-2.4	1.0	1.0	-3.4***

Van der Woude Syndrome: A Case Study

obtain a class I cuspid relationship, achieve stable posterior intercuspation, correct his transverse maxillary discrepancy (and prepare the patient for secondary alveolar bone grafting), obtain an acceptable overbite and overjet, relieve crowding, correct incisor angulation, facilitate restoration of missing teeth, correct his midlines and monitor his growth.

A treatment plan was set forth to band and bond both arches, level and align, and evaluate growth so that the need for orthognathic surgery could be assessed. To correct the bilateral posterior crossbite, rapid palatal expansion was indicated. Impressions were taken and the Hyrax palatal expander was inserted on 10/16/06. To increase maxillary arch width, transverse biomechanical forces were applied; enough orthopedic force would cause separation of the midpalatal suture.⁷ It has been determined that transverse discrepancies should be treated early in life to allow normal expression of mandibular and maxillary growth.⁸ Palatal expansion was completed one month later on 11/17/06 and significant expansion was seen (*Figures 3a and 3b*). In patient BS, maxillary expansion also facilitated the second-

ary alveolar bone graft, which was performed on 11/15/07. Extraction of #7 was a sequela of the bone graft procedure. A removable transpalatal arch was inserted prior to bone grafting, which functioned to maintain expansion while allowing the surgeon access to the palate.

Three months after the bone graft, BS resumed orthodontic care. A fistula was noted at this time through the original left cleft site; a complication of palatal expansion. The fistula could be seen clinically as well as via periapical and a panoramic radiograph taken with gutta percha through the graft site (*Figure 4*). Graft revision was indicated and was to be addressed during the planning of the patient's upcoming orthognathic surgery.

Figure 3A

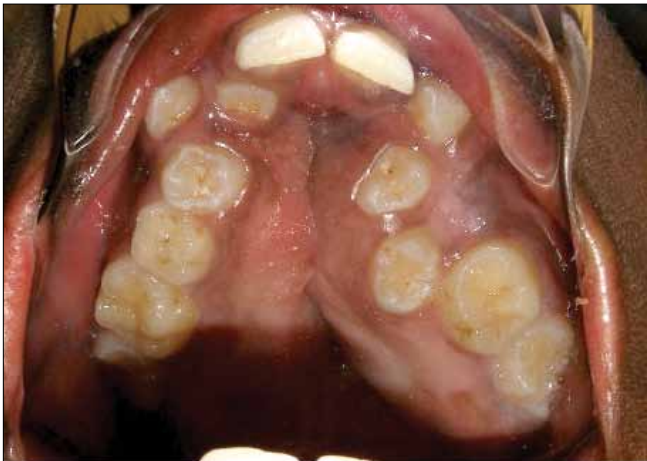

Figure 3B

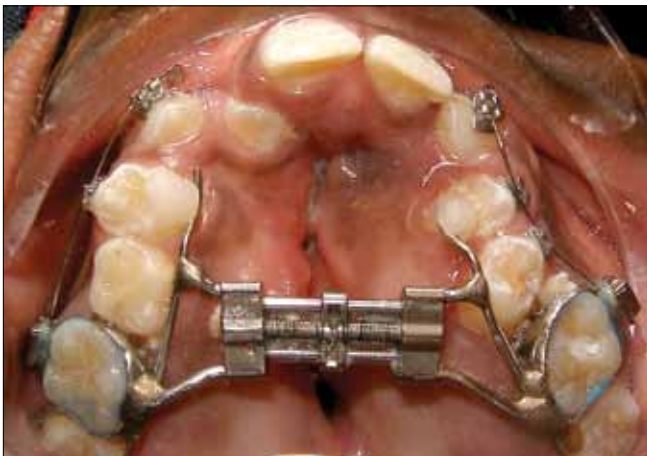

Figure 3a and 3b Pre- and post-palatal expansion, respectively demonstrating increased arch width following use of a Hyrax expander.

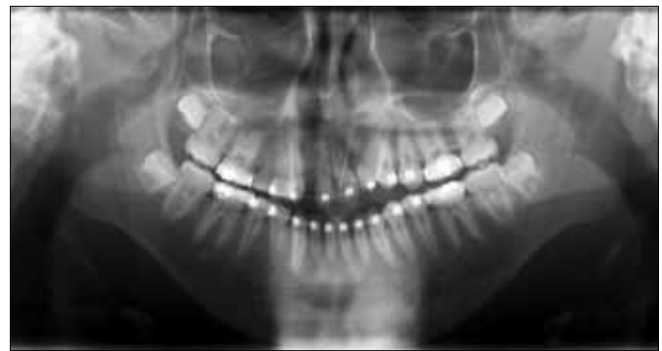

Figure 4 This Panoramic radiograph taken 3/31/08 shows the fistula that has formed following expansion. A gutta percha cone can be seen superimposed on tooth number 9, defining and describing the fistulation site. This will be addressed during B.S. upcoming surgery.

At this time, 17½-year-old BS demonstrated an SMI of 11 indicating completion of skeletal growth. He would be prepared for a two-jaw orthognathic surgery. The maxillary surgery would be a three-piece LeFort I osteotomy. Although this procedure is rarely done in bilateral cleft patients due to their compromised blood supply, the decision was made to proceed due to the difficulty in completely leveling the maxillary arch orthodontically.

Discussion

To make a diagnosis of Van der Woude syndrome, one of the following three findings must be present: 1) Lip pits and cleft lip and/or palate. Lip pits must be paramedian on the lower lip, and can include mounds with a sinus tract leading from a mucous gland of the lip. 2) Lip pits alone with a first degree relative with cleft lip and/or palate. 3) Cleft lip and/or palate and a first-degree relative with lip pits.⁴ This patient presented with lip pits as well as cleft lip and palate, which gives a clinical definitive diagnosis of VWS.

Several other non-classical phenotypes of VWS have been identified. One study showed that as high as 81% of patients with VWS present with hypodontia.⁹ This can be seen the case of patient BS, as he was missing succedaneous

Van der Woude Syndrome: A Case Study

teeth #4 and #10. Other manifestations associated with VWS are bifid uvula and submucous clefting, both of which were also evident in this patient. Many more presentations of VWS, though not present in this case, have been observed and noted in the literature. These include: conical elevations of the lip, ankyloglossia, limb abnormalities, and hearing loss.^{8,9,10,4,11,12} The wide range of signs and symptoms associated with VWS demonstrates the large amount of variable expressivity that can occur within this syndrome. The penetrance was found to be 96.7%.¹³ In a seven-generation study, 88% of individuals affected by VWS showed lip pits, and in 64% of the cases, this was the only manifestation.¹⁴

The variable expressivity of this disease means that a patient can present clinically with apparent, full-blown VWS and all the possible associated conditions, or with extremely small, undetectable lip pits in conjunction with submucous clefting. This leads to a situation where VWS is frequently underreported and underdiagnosed, which can be detrimental to a child's development. Submucous clefting is an abnormality in the muscle attachments of the soft palate, with an intact oral and nasal mucosa. Generally, this is a treatable condition, but when undiagnosed it can lead to facial growth abnormalities, feeding difficulties, speech abnormalities, and disease of the middle ear. The disease of the middle ear results from the dysfunction of the Eustachian tubes due to the abnormalities of the muscle attachments.¹⁵ This should prompt both the medical and dental community to be aware of lower lip pits, as well as understand its correlation with VWS and submucous clefting. Detection of submucous clefting, especially early detection, can allow for muscle reconstruction at a younger age and a better prognosis for speech capabilities.^{16,17} One study found that 27% of the individuals who had VWS presented with submucous clefting.¹⁸ This is considered to be a significant percentage of cases and is an important reason why those individuals who have family members with VWS are encouraged to go for meticulous examination for lip pits, as well as genetic counseling.

The idea of genetic counseling for VWS patients is still relatively new, as it was not until recently that the offending gene was unequivocally determined. To determine if this syndrome was allelic or not, monozygotic twins were studied. One of the twins showed the VWS phenotype, the other twin was normal, and both parents were unaffected. Genetic sequencing was performed and a mismatch was found in the gene sequence leading to the discovery of a nonsense mutation found in the IRF6 gene. To help solidify this information, 45 additional unrelated families with VWS were sequenced and found to have allelic mutations in the same gene.¹⁹ IRF6 genes have been well described with their role in cellular defense, but their exact role during development is unknown.^{19,20} The association between IRF6

mutation and VWS patients with craniofacial deformities suggests an important role in for the IRF6 gene in craniofacial development.

Conclusion

Van der Woude Syndrome (VWS) is the most frequent form of syndromic clefting and accounts for approximately 2% of all cleft lip and palate cases.^{1,2} This report illustrates that the treatment of cleft lip and palate requires a multi-disciplinary, team-oriented approach, which may last for many years. The patient presented in this case report began therapy with cleft lip and palate surgeries before the age of one, and has been through alveolar bone grafts, speech therapy, Rapid Palatal Expansion, and orthodontics in preparation for bilateral alveolar bone grafts and orthognathic surgery at age 17 to correct the maxillary and mandibular jaw discrepancies that still exist.

Several pre-surgical orthodontic treatment objectives have now been completed (*Figure 5*). The posterior crossbites have been corrected, crowding has been alleviated, inci-

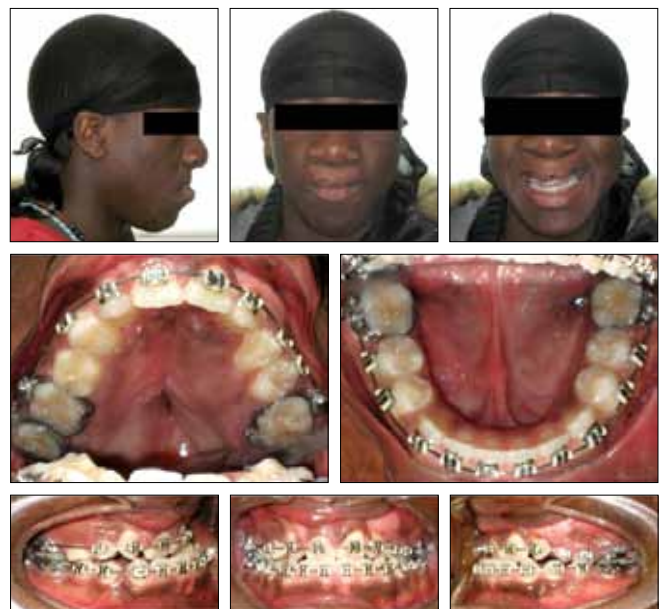

Figure 5 Progress composite photographs (3/23/09) showing completion of pre-surgical orthodontic treatment.

sor angulations have been corrected, and midlines are now coincident. A pre-surgical lateral cephalogram accompanied by the Columbia Analysis measurements was used to help determine if proper dental decompensation was accomplished (*Figure 6a and 6b*). Incisor angulation was an important parameter used to assess appropriate pre-surgical dental treatment. These measurements included the interincisal angle (U1-S1), L1-GoGn, and U1-SN. *Figure 6b* verifies that these measurements have been adjusted to an acceptable pre-surgical value, demonstrating almost complete dental decompensation. This patient was scheduled

Van der Woude Syndrome: A Case Study

Figure 6A

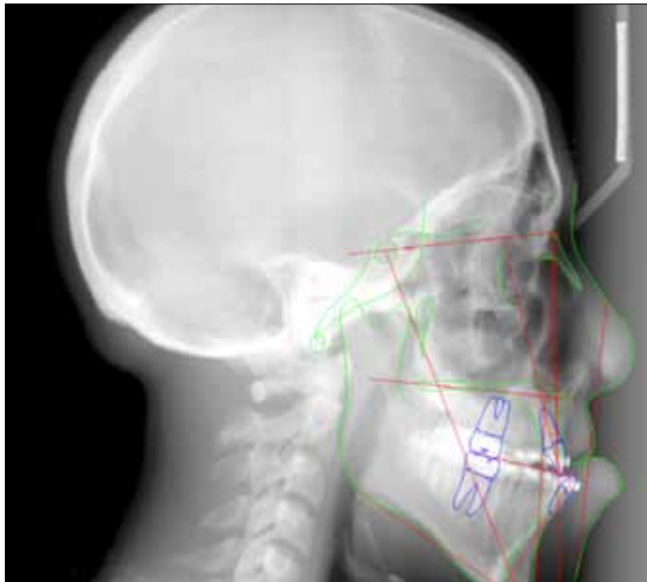


Figure 6B

Group/ Measurement	Value	Norm	Std Dev	Dev Norm
SNA (°)	84.9	81.0	4.0	1.0*
SNB (°)	81.0	78.0	3.0	1.0*
ANB (°)	4.0	3.0	2.5	0.4
Wits Appraisal (mm)	-2.9	1.0	3.0	-1.3*
SN-GoGn (°)	37.9	32.0	5.0	1.2*
SN-Palatal (SN-PP) (°)	11.3	8.2	3.3	0.9
Palatal-Mand Angle (PP-GoGn) (°)	26.7	22.0	6.0	0.8
Y-Axis (SGn-SN) (°)	73.3	67.0	5.5	1.1*
P-A Face Height (S-Go/N-Me) (%)	61.9	65.0	4.0	-0.8
UAFH/LAFH Ratio % (N-ANS/ANS-Me)	77.8	80.0	7.0	-0.3
U1-SN (°)	98.9	103.5	5.0	-0.9
Interincisal angle (U1-L1) (°)	130.6	130.0	5.0	0.1
L1-GoGn (°)	92.5	93.0	6.0	-0.1
L1 Protrusion (L1-APo) (mm)	10.9	1.0	2.0	5.0*****
L1 -NB (mm)	13.0	4.0	1.8	5.0*****
Pog-NB (mm)	-2.0	4.0	1.5	-4.0****
Holdaway Angle (NB to H-line) (°)	3.5	8.0	4.0	-1.1*
Holdaway Ratio (L1-NB:Pg-NB) (%)	-6.5	1.0	1.0	-7.5*****

to undergo orthognathic surgery, which will address the clinically unacceptable skeletal structure that orthodontics cannot treat. To complete this case, retention was indicated to help maintain the final occlusion.

References

- Schutte BC, Sander A, Malik M, Murray JC. (2005) Refinement of the Van der Woude gene location and construction of a 3.5-Mb YAC contig and STS map spanning the critical region in 1q32-q41. *Eur J Orthod.* 3: 507-14.
- Rizos M, Spyropoulos MN. (2004) Van der Woude syndrome: a review. Cardinal signs, epidemiology, associated features, differential diagnosis, expressivity, genetic counselling and treatment. *Eur J Orthod.* 26: 17-24.
- Genetics Home Reference. Van der Woude Syndrome. Reviewed April 2008. Available at: <http://ghr.nlm.nih.gov/condition/van-der-woude-syndrome#definition>. Published February 6, 2001.
- Schinzel A. and Klauseler M. (1986) The Van der Woude Syndrome (Dominantly Inherited Lip Pit and Clefts). *J Med Genet.* 23(4): 291-294.
- Gene Reviews. IRF6-Related disorders. Initial Posting October 20, 2003. Available at: <http://www.ncbi.nlm.nih.gov/books/NBK1407/>. Updated May 15, 2006.
- L.S. Fishman. (1982) Radiographic Evaluation of Skeletal Maturation. *The Angle Orthodontist.* 52:88-112.
- Bell R. (1982) A Review of Maxillary Expansion in Relation to Rate of Expansion and Patients Age. *American J. Ortho.* 81(1):32-7.
- Efstradiatis S. (1986) The Role of Facial Growth in Orthodontic Treatment. *New York Journal of Dentistry.* 56(3): 16-18.
- Schneider E. (1973) Lip Pits and Congenital Absence of Second Premolars: Varied Expression of Lip Pit syndrome.
- Ranta R. and Rintala AE. (1983) Correlations between the microforms of the Van der Woude syndrome and Cleft Palate. *Cleft Palate J.* 20(2): 158-62.
- Burdick AB, Ma LA, Dai ZH, Gao NN. (1987) Van der Woude syndrome in two families in China. *J Craniofac Genet Dev Biol.* 7(4):413-8.
- Kantaputra P, Sumitsawan Y, Schutte B, Tochareontanaphol C. (2002) Van der Woude syndrome with Sensorineural hearing loss, large craniofacial sinuses, dental pulp stones, and minor limb abnormalities. *Am J Med Genet.* 108(4): 275-80.
- National Center for Biotechnology Information. Van der Woude Syndrome. OMIM. Initial Posting July 4, 1986. Available at: <http://www.ncbi.nlm.nih.gov/omim/119300>.

Figure 6a and 6b Pre-surgical Lateral Cephalogram tracing and Columbia Analysis measurements demonstrating appropriate pre-surgical dental decompensation.

Van der Woude Syndrome: A Case Study

14. Janku P, Robinow M, Kelly T, Bralley R, Baynes A, Edgerton MT.(1980) The Van der Woude Syndrome in a Large Kindred: Variability, penetrance, genetic risks. *Am J Med Genet.* 5(2):117-23
15. Moss A, Piggott W, Jones K.(1988) Submucous Cleft Palate: A treatable condition that is commonly missed. *British Med J.* 297: 85.
16. Weatherley and White. (1976) Submucous cleft palate. J, ed. *Recent advances in plastic surgery.* 58-67.
17. Porterfield HW and Trabue JC.(1965) Submucous cleft palate. *Plast Reconstr Surg.* 35:45-50.
18. Lam AK, David DJ, Townsend GC, Anderson PJ . (2010). Van der Woude syndrome: dentofacial features and implications for clinical practice. *Australian Dental Journal.* 55: 51-58.
19. Kondo S. (2002). Mutations in IRF6 cause Van der Woude and Popliteal Pterygium syndromes. *Nat Genet.* 32:285-89
20. Taniguchi T, Ogasawara K, Takaoka A, Tanaka N.(2001) IRF family transcription factors as regulators of host defense. *Ann Rev Immunol.* 19:623-55.

Successful Osseointegration and Prosthetic Loading of a Temporomastoid Implant in the Treatment of Congenital Hemi-Anotia: A Case Presentation

Steven Nadler¹, Lauren Midthun¹, John H. Evans DDS², Yuko C. Nakamura DMD, MD³, Candice Zemnick DMD, MPH, MS⁴

¹Class of 2011, Columbia University College of Dental Medicine, New York City, New York, NY

²Assistant Professor, Division of Prosthodontics, College of Dental Medicine, Columbia University, New York, NY

³Chief Resident, Division of Oral Surgery, College of Dental Medicine, Columbia University, New York, NY

⁴Assistant Professor, Director of Predoctoral Prosthodontics, Maxillofacial Prosthodontist, Division of Prosthodontics, College of Dental Medicine, Columbia University, New York, NY

Abstract

This article presents the case of a healthy patient with a congenitally missing ear who received a percutaneous, osseointegrated implant in the temporomastoid region to support a magnet-retained auricular prosthesis. The report discusses why the patient was an ideal candidate for an implant-supported auricular prosthesis by examining the rationale behind this selection, along with the surgical method and the prosthetic reconstruction guidelines. In addition, the importance of post-surgical home care instruction and one year follow-up will be reviewed.

Case Presentation

HM was a 44 year old Hispanic male who presented with congenital agenesis of the right ear pinna, auditory canal, tympanic membrane, in addition to ossicle malformation on the right side. (Figure 1) Incomplete pinna formation, or

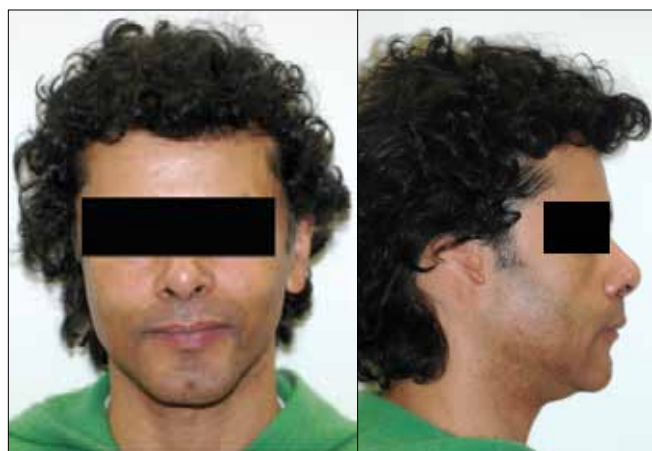

Figure 1 HM frontal view and profile view

microtia, can be graded based on severity. HM had a severe malformation and was classified as grade III. (Figure 2) His past medical history was otherwise unremarkable. Past surgical history includes hernia repair, lipoma resection from the back and an unsuccessful attempt to reconstruct an ear from his costal cartilage about 20 years ago. He had no known drug allergies and took Wellbutrin for depression. The maxillofacial prosthetics team at Columbia Presbyte-

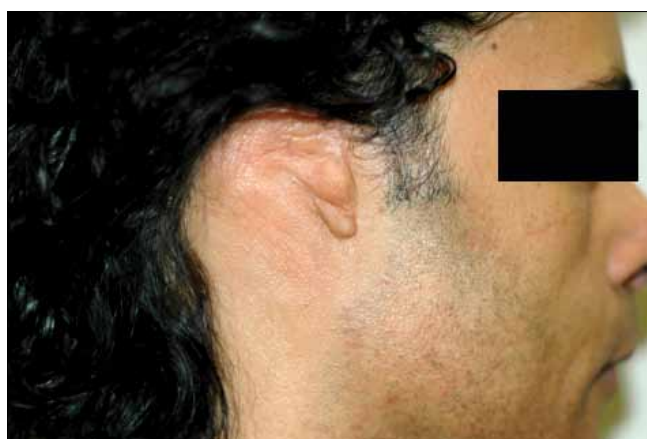

Figure 2 HM in profile. Note almost complete agenesis of the right ear

rian Hospital (Dr. John Evans, prosthodontist, and Mr. Eric Asher, anaplastologist) worked with Dr. Yuko Nakamura, oral surgeon, to complete treatment.

Materials and Methods

HM was an ideal candidate for an implant supported prosthesis (ISP) due to his overall good health, adequate quality and quantity of bone in the right temporomastoid region as revealed by CT scan, and his psychological commitment to seeing treatment through to the end. He has remained compliant with proper home care and has kept in contact with the team through recommended check ups and monitoring. HM was selected for the single-stage procedure (in which both fixtures and abutments are placed on the same day), as opposed to the two-stage, because the implant site was never exposed to ionizing radiation and he has the manual dexterity and the cognitive abilities to care for the surgical site as directed. Therefore, the longer healing time offered in the two-stage procedure was not necessary.

Three Straumann pure titanium self-tapping threaded implant fixtures, measuring either 3 or 4 mm in length with a diameter of 3.3 mm and a flange at the appropriate length, were used as fixtures for three abutments to support the prosthesis. The fixture can accommodate different angula-

Successful Osseointegration and Prosthetic Loading of a Temporomastoid Implant in the Treatment of Congenital Hemi-Anotia: A Case Presentation

tions of abutment placement. The flange ensures that the cranial vault or mastoid air cells are not perforated. Surgical templates were placed prior to surgery by the prosthodontist and prosthetic technician; the templates were especially important in this case because the patient lacked an external auditory meatus as a landmark for implant placement. (Figure 3) During surgery, desired implant locations were marked by injecting methylene blue under the periosteum through prepared template guides. Implant placement was planned so that the fixtures would rest under the antihelix and antitragus of the prosthesis. (Figure 4) Alternative locations are possible if the selected locations are found to inter-

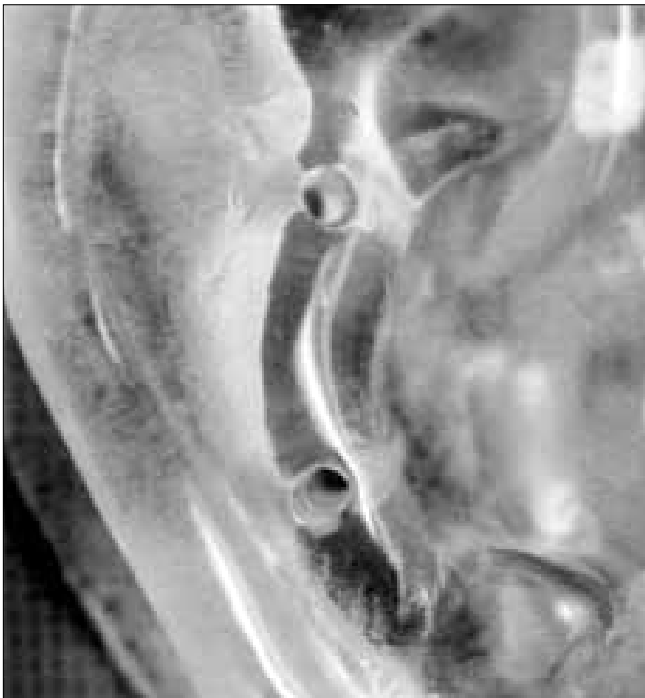

Figure 3 Surgical template

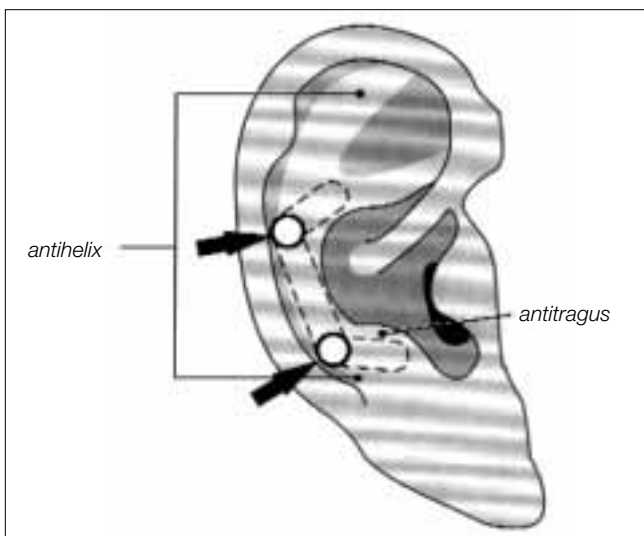


Figure 4 Diagram of the two preferred locations for fixture placement

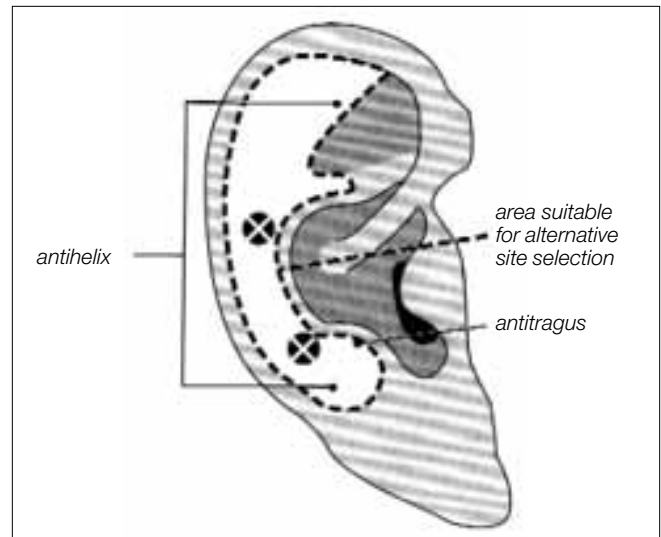


Figure 5 Alternative fixture locations based on determined necessity during surgery. Care must be taken to stay in the high-contoured spots of the prosthesis.

ferre with the contours of the prosthesis. (Figure 5) Hearing tests confirmed that the patient had moderately severe to profound mixed hearing loss in the right ear, with a conduction average of 34 dB HL over 0.5, 1, 2, and 3 kHz, and a 72% word recognition. In the left ear, he had normal hearing through 2000 Hz with 100% word recognition. Because HM's bone conduction measurements for the right ear averaged only 34 dB HL (45 db HL is the minimum threshold), he was not a candidate to receive a bone anchored hearing aid (BAHA).⁸

Surgical Protocol

The two-stage procedure was the first standard auriculo-temporal implant placement protocol published by Tjellstrom in 1985, with a reported osseointegration rate of 97-100%. 85% of patients reported no adverse hyperplastic or inflammatory skin reactions surrounding the implants. In 1991, Goteburg introduced the concept of a one-stage procedure in which both fixture and abutment are placed simultaneously. Osseointegrative success and skin reaction rate were similar to that found for the two stage procedure, leaving the main difference between the two approaches in patient selection.⁸ The two-stage procedure is preferred for children and patients who have been exposed to ablative radiotherapy in the region of the future implants, as these candidates have decreased bone density and impaired medullary circulation, respectively. A healing time of 3-6 months is allowed between implant and abutment placement to increase likelihood of implant success.⁹

The ideal diameter of the implants is 5.5 mm, with length being 3.3 mm.⁷ A 2 mm round bur at high speed (approx 2000 RPM) is used for initial location of implant sites, as guided by the methylene blue stain injected from a 3 cc

Successful Osseointegration and Prosthetic Loading of a Temporomastoid Implant in the Treatment of Congenital Hemi-Anotia: A Case Presentation

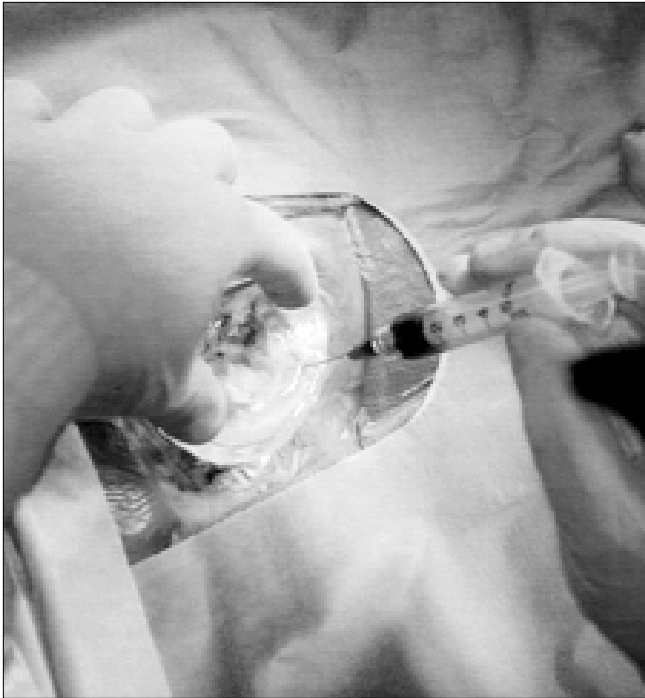

Figure 6 Injection of methylene blue under the periosteum.

syringe into the periosteum. (Figure 6) A 22 gauge, 1.5 inch needle is driven through the strategic openings in the template onto the exposed periosteum.¹ A 15 RPM low speed handpiece is then used to finalize the width of the prepared osteotomies and place the fixtures. The sites are prepared under copious irrigation to cool the bone and lessen the likelihood of necrotic changes.¹¹ Self-tapping or self-threading implants are preferred if the bone is very brittle or excessively dense (i.e. Type I cortical bone). Size and location of the flap is determined using the preformed prosthetic template as a guide. The titanium fixtures are inserted to a depth of 3-4 mm in the temporal bone. Guide drills of 4 mm in length are preferred for most adult patients. Due to the thinner cortices in pediatric patients, the guide drill should be 3 mm in length. Primary stability is accomplished via 15 N-cm minimum of insertion torque.¹¹ The Lundgren protocol specifies that implants should be inserted about 18 mm away from the external auditory meatus, and staggered at positions of six, nine, and twelve o'clock for the right side and twelve, three, and six o'clock for the left. The distance from the center point of any given fixture to its neighbor should be 11 mm in length if 3 implants are used, or 15 mm if two implants are used, depending on the retentive design chosen for the prosthesis.¹ (Figure 7) A fourth implant may be added if a BAHA is being installed.¹¹

If the procedure is performed in one-stage, the surgeon removes excess tissue bulk to provide a maximum combined skin and subcutaneous tissue thickness of 2 mm. The thinned tissue is then positioned so that the implants are

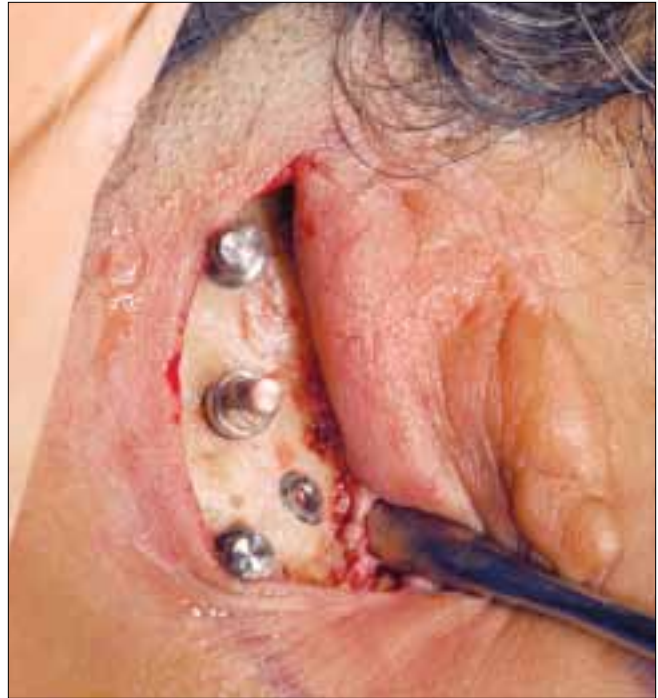

Figure 7 HM, screw fixtures in place with inferior abutment about to be placed

covered once more. In burn victims or those with pre-existing scar tissue, the surgeon may not need to spend much time on the thinning process. As with intraoral implants, a major cause for extraoral implant failure is epithelial migration between the bone and the screw, which interferes with osseointegration. The likelihood and severity of this effect is

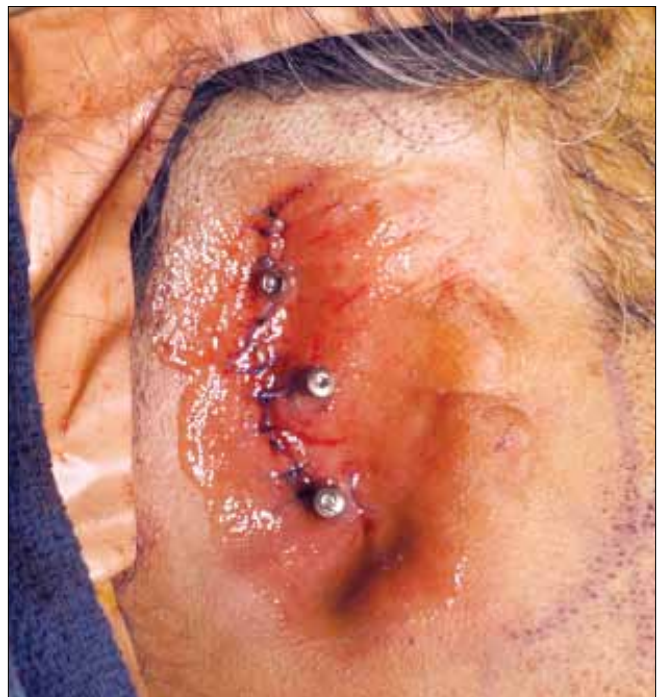

Figure 8 HM, Post op with healing abutments in place.

Successful Osseointegration and Prosthetic Loading of a Temporomastoid Implant in the Treatment of Congenital Hemi-Anotia: A Case Presentation

minimized by intra- and post-operative efforts to maintain taut tissue circumscribing the implants.¹ If there is not enough skin of desired quality to bury the implants initially, then an autogenous, split-thickness skin graft (ideally devoid of hair follicles) is obtained. The graft is similarly thinned and then sutured over the fixtures such that it directly overlies bone. The healing abutments are attached to the fixtures by directly penetrating the skin over the implant sites. (*Figure 8*) The skin can be cut with an 11 Bard Parker blade or broken using a punch biopsy tool (i.e. 4 mm diameter dermal punch). Once the fixtures are exposed, the abutments are screwed down into position, and the tissue around the implant is sutured to facilitate both healing and drainage of an unanchored end of tissue immediately contacting the fixture.¹¹

Bacitracin, Terracortil, Polymixin B or similar antibiotic ointments are applied to xeroform gauze, which act as a pressure dressing to ensure close apposition of the sutured skin with the underlying periosteum.¹¹ A larger pressure dressing is wrapped over the patient's head and kept in place for 24 hours following surgery.⁸ Both dressings are essential to ensure adequate hemostasis and prevent infection. After 24 hours, the large pressure dressing can be removed. A localized dressing is used and changed regularly for one week after surgery, at which time sutures are removed and the patient can apply antibiotic ointment four times daily. After the dressing and sutures are removed, the patient is encouraged to gently clean the collar of debris around the abutments with an extra soft toothbrush, cotton tip soaked in soap and warm water, and/or 3% hydrogen peroxide solution.¹¹ The patient is brought in for follow-up by the surgeon and maxillofacial prosthetics team three to four times during the first year and twice a year after. A BAHA can be attached about two months after the surgery or whenever soft tissue is sufficiently healed.⁸ Prosthetic loading, accomplished by wearing the final prosthesis, can usually begin 3-6 months after the surgery, provided that the CT scans reveal evidence of sufficient osseointegration. The patient begins visits with the prosthetic team at this time, and receives the final prosthesis in a matter of weeks.¹¹

Possible complications arising from fixture placement in the temporomastoid area include puncture of the mastoid air cells, typically found in the inferior mastoid process (the most common adverse effect with 28% occurrence rate), penetration or tearing of the dura mater lining the middle cranial fossa (7.3%) with resultant CSF leakage (0.3%), and exposure of the sigmoid sinus (1.3%).⁸ These communications can be repaired intraoperatively.⁷ Also, temporal branches of the facial nerve may be damaged during the procedure, but the chances of this complication are practically nil (reported at 0%).⁸ To lessen the likelihood and severity of these unwanted effects, preoperative CT scans are assessed for any aberrant morphology of the sigmoid sinus, the amount of bone

between the greatest depth of the fixture and the dura, and the proximity of the implant sites to the stylo mastoid foramen where nerve VII exits the skull. If implant locations must be adjusted during surgery, the prosthetist and/or prosthodontist will be present in the operating room to guide the repositioning of the prepared template to ensure successful restoration of re-calibrated guide points.¹

Studies show that anywhere from 3-60% of patients undergoing placement of auricular implants experience inflammatory soft tissue reaction in the skin that circumscribes the abutments, but in most cases (95.6%) this is kept in check by adherence to the homecare protocol as outlined above.⁷ Patients experiencing more severe forms of this reaction that are not amenable to changes in hygiene measures alone (Holgers score 3+) likely need surgical removal of excess tissue (chemical or electrical cauterization of granulation tissue) and possible grafting to maintain thin, taut soft tissue lining of the abutments (*Table 1*). Patients also can be placed on a standard oral antibiotic or antifungal regimen to prevent recurrent infection of the site by microbes such as *S. aureus*, *Streptococci*, and *Candida* species. Topical steroids may soothe irritation in peri-implant tissue in the short run.⁷ The ultimate goal is to minimize excessively mobile or bulky soft tissue and to ensure that all grafted tissue adheres tightly and directly to the underlying bone. Discouraging the patient to applying makeup, hair products or other potentially irritating substances near the attachment sites helps to minimize soft tissue flare-ups.⁹

Prosthetic Protocol: Pre-operative

The clinical team examines the auricular defect and using color transfer applicators and the contralateral ear as a guide, marks the inferior, superior, anterior and posterior points along what will become the border of the final prosthesis. (*Figure 9*) The prosthodontist ensures the transfer of the outline to the initial impression of the defect, and then ultimately to the working cast. With the patient in the supine position (simulating the surgical environment in which the stent will be aligned), the prosthetic team takes a polysulfide impression of the auricular defect and pours it up in type III stone. They also impress the contralateral ear and create a corresponding stone cast for comparative purposes. After applying a silicone separating medium to a cast of the intended surgical site, the anaplastologist uses tinted skin-colored baseplate wax to create a wax pattern for the future prosthesis. After sculpting desired contours, the wax is made smooth by flaming. The team then places the prepared pattern directly on the patient and modifies it as necessary. The alignment of the wax pattern, and ultimately the final prosthesis, should be inspected from all angles to ensure that facial harmony and symmetry with the natural ear is maximally preserved.

Successful Osseointegration and Prosthetic Loading of a Temporomastoid Implant in the Treatment of Congenital Hemi-Anotia: A Case Presentation

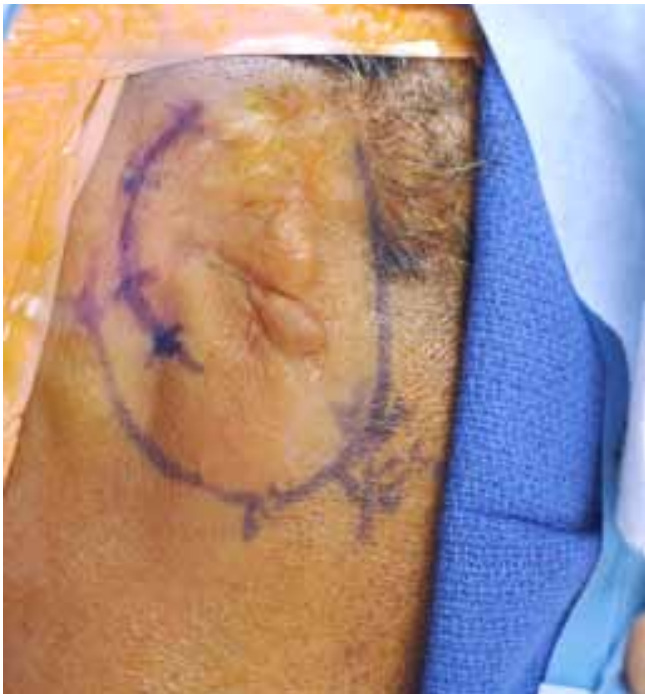

Figure 9 HM, Pre-op with inferior, superior, anterior, posterior points of final prosthesis border marked.

Table 1 Holgers Scale of Peri-Implant Soft Tissue Reaction and Desired Treatment⁸

Grade of Response	Appearance	Treatment
0	no reaction	None
1	erythema of skin around implant	<ul style="list-style-type: none"> reinforce home care instructions provide patient with earlier follow up date
2	erythematous, moist surface of skin around implant	<ul style="list-style-type: none"> reinforce home care instructions set earlier follow-up appt topical application of antibiotics (Terracortil + Polymixin B + hydrocortisone) and/or antimycotics (if Candida) and/or hydrocortisone
3	formation of granulation tissue around implant	<ul style="list-style-type: none"> excise granulation tissue *Wrap gauze with Terracortil + Polymixing around affected abutments for one week OR replace with healing abutments wrapped in gauze
4	extensive soft tissue reaction/ infection	<ul style="list-style-type: none"> remove implant

Post-Operative

After the requisite healing time has passed, the patient returns to the prosthetic team for delivery of the final prosthesis. The pre-established retentive design for the prosthesis (i.e. bar-and-clip, magnet or combination of the two) determines the next steps. First, an abutment-level impression is made using appropriate copings and guide pins. The retentive substructure of the prosthesis is made prior to creation of the final esthetic product.¹¹ Because there is greatest bulk of silicone material in the antitragus and antihelix regions of the prosthesis, fixtures are usually aligned below these structures. If the bar and clip design is used, gold cylinders are cast and attached to the fixtures. A wax pattern of the desired length of the retentive bar is made directly on these cylinders, then burned out and cast with type III gold alloy. This gold foundation is then attached to the fixtures. Retentive clips built into the underside of the final silicone prosthesis are used to attach the prosthetic ear to the bar. If magnet-based retention is desired, then magnet keepers are built into an acrylic or composite substructure that becomes the base of the silicone prostheses. Their position matches exactly with corresponding magnetic heads that remain attached to the fixtures.¹¹

Results

The fixtures and healing abutments were placed in a single-stage surgery on 12/29/08. Approximately 3-4 months later, the Columbia prosthetics team began fabricating the final prosthesis with magnetic retention. HM was fully cooperative with the clinicians' directions and followed homecare protocol well. He has been satisfied with the prosthesis on esthetic and functional levels until recently (approx 1 year after placement) when the response of tissue immediately surrounding the implants reached Holgers Class 3, and as a result the skin was pinched each time the patient snapped the prosthesis into place. A second surgery was planned to dissect away hyperplastic tissue and replace it with a split-thickness graft from the leg or from behind the other ear. The patient will wear the prosthesis during waking hours once the grafted tissue has healed.

Discussion

The concept of osseointegration was first investigated by Swedish orthopedist PI Branemark in 1965 and introduced publicly in the late 1970's as a means to treat edentulism through implant supported dental restorations.² As early as 1977, endosseous root form implants were first used to hold auricular prostheses in place and to support BAHA devices.⁵ However, it was not until 1985 that the FDA officially recognized the use of dental implants in the restoration of extraoral craniofacial defects.⁸ Branemark's discovery demonstrated the ability of bone to "osseointegrate," growing between the threads of a screw to provide anchorage and stability. Modifications to the original model have

Successful Osseointegration and Prosthetic Loading of a Temporomastoid Implant in the Treatment of Congenital Hemi-Anotia: A Case Presentation

included the use of titanium alloy with its proven superior strength, and the employment of various shapes and surface treatments to increase the surface area available to osseointegrate. Unlike dental implants, which are composed of $TiAl_6V_4$ alloy, most craniofacial fixtures are made of commercially pure titanium. Similar to dental implants, they are threaded for primary stability and can be machine surfaced to enhance the speed of integration. A popular design includes a collar or coronal flange in the fixture that keeps the implant from settling deeper into the bone after placement.⁹

It is important to realize that auricular implant supported prostheses are only one of several possible extraoral uses for dental implants and their derivatives. The temporal bone is generally accepted as the most predictable site in the craniofacial skeleton for successful osseointegration (rates of 92-98%), due to abundant vasculature and increased density of cortications.⁹ This is followed by the orbit (90-96%) and finally by the nasal region (70-80%).⁷ Orbital or superciliary implants are generally confined to the superolateral orbital rim, as the medial portion of the orbit contains the ultra-thin lamina papyracea and houses the lacrimal fossa with its underlying gland. It difficult to obtain adequate bony anchorage for nasal implants, and the resultant retentive elements can be more difficult to clean because of the abundant soft tissue and mucosal secretions in the region. Regardless of placement site, the quality and quantity of bone in patients can be affected by local exposure to radiation or by systemic conditions that decrease bone density (e.g. osteogenesis imperfecta, osteoporosis) or adversely affect circulation. In addition, the etiology of the loss of an extraoral structure (e.g. due to cancer resection with radiotherapy, trauma or congenital/syndromic conditions) affects the relative positioning of nearby vital structures such as craniofacial sinuses and major blood vessels and nerves, as well as development of soft tissue pathology (e.g. excessive scar tissue) that must be surgically removed to ensure success of the case.⁷ Patients must be carefully evaluated for diabetes mellitus, history of steroid use, chemotherapy or radiation, all of which may detract from the healing capacity of the implant site and the potential of new bone to grow around the fixtures. It should be noted, however, that because the rate of osteoradionecrosis is very low in craniofacial structures, previous exposure to ionizing radiation is not an absolute contraindication to implant placement, especially in the auricular area. It is generally accepted that the surgeon wait 6-19 months after completion of radiotherapy before fixture placement,⁷ and radiation shields can be fabricated by the prosthodontist to reduce exposure to implant sites prior to ablative therapy.¹¹

With regard to auricular implants, the design of retentive features depends on patient lifestyle and expectations, as well as the ability of the prosthesis to mask underlying

metallic components. The number and orientation of the fixtures to one another, together with the structure of the retentive assembly, must direct loading forces in such a way that the bone surrounding the fixtures is preserved and the prosthesis functions optimally. In general, extraoral implants are more vulnerable to traumatic insults from the outside environment than are dentoalveolar implants, especially in younger patients with active lifestyles. While intraoral implants are subject to continuous, cyclic application of intermediate-level forces from mastication, extraoral fixtures may receive very light loading the majority of the time but can experience sudden high impact or velocity forces due to contact with external objects.¹⁰ Force should be channeled perpendicular to the plane of the implant/bony interface whenever possible. Tension, bending, and laterally-directed forces can adversely affect the implant lifespan and can develop if stresses are not shared evenly by each fixture (e.g. a cantilever is created). If more than two fixtures are placed, they should be staggered (e.g. in HM's case, the implants form the traditional tripod outline). Two implants suffice for most bar-and-clip systems, with the intervening bar acting as a beam or "splint" that facilitates sharing of stress equally between the two fixtures.¹¹ In order to avoid creating a cantilever, the bar must pass from the center, as opposed to the tangent, of one abutment to another, which is only possible if the abutments are parallel to each other. Three implants are generally more stable than two, and the established maximum distance between the centers of implants (e.g. 15 mm if two implants and 11 mm if more than two implants) helps to minimize any cantilever effect.⁹ Patients with compromised neuromuscular coordination are more likely to benefit from the 3-4 fixtures, magnetically-retained design, as it is easier to remove and replace the prosthesis and to clean around the abutments. The magnets also allow for a consistently higher level of retentive stability in the long run. In contrast, the bar and clip setup has greater short-term retention but components are more likely to loosen and have to be replaced over time. Magnetic attachments require less room between the prosthetic antihelix and the underlying tissue, and are preferred in cases where there is less than 9 mm of available space. When the abutments of neighboring implants have different angulations, the magnet design is chosen as it does not involve generation of cantilever forces in such cases.¹¹

Chung et al. reports development of a novel retentive design combination featuring individual magnets that are laser-welded to fit inside a 4 mm-thick composite bar. The authors claim that the composite is less likely to fracture than the unfilled acrylic that is traditionally used in retentive substructures. In this design, the magnets on the intaglio surface of the prosthesis do not directly contact the abutments attached to the implants, but interact with the corresponding magnets embedded in the bar nearby. Chung

Successful Osseointegration and Prosthetic Loading of a Temporomastoid Implant in the Treatment of Congenital Hemi-Anotia: A Case Presentation

et al. proposes that this design provides space for increased numbers of magnets of varying sizes, allowing for greater stability of the prostheses when seated and greater ease of prosthesis application and removal. In the future, more designs will allow the combined benefits of bar-and-clip and magnetic attachment devices for auricular prostheses.³ Non-traditional juxtaosseous implants, developed from osteosynthesis plates, rely on a flat, 1 mm thin geometry and may be a useful alternative to root form implants in sites with a lesser volume of adequate bone. An experimental slant-lock retentive system for auricular implants has also been introduced, allowing the prosthesis to benefit from greater passivity during initial insertion and a more active or stronger fit when it fully engages the retentive substructure. The goal of this system is to increase the ease of insertion and decrease rates of unwanted dislodgement. However, because the slant/lock design enables less 'give' between the prosthesis and its bone-anchored foundation during minor movements, the non-metallic parts of the prosthesis (silicone, acrylic) bear most forces and are damaged more easily.⁴

Lastly, it is important to consider the durability of the implant-supported auricular prostheses themselves, as each successful case depends not only on solid osseointegration, but also the flexibility and composition of the prosthesis. In their study of the lifespan of different subsets of craniofacial prostheses, Karakoca et al⁶ reported that nasal prostheses had the longest mean survival time (17.6 months), followed by auricular (14.1 months) and then orbital (13.4 months). Moreover, they found that patients in all three categories were most likely to need a second prosthesis due to silicone tears and dislodgement or fracture of the retentive substructure (combined rate of 43%), followed by unfavorable changes in color (32.3%). In cases where problems developed with the second prosthesis, the most likely issue was also unwanted color change. When the 32 auricular cases were considered separately, the most common reason for a first replacement was one or more loose abutments (40.6%), followed by loose bar screws (29%), and breaks between the substructure and overlying silicone (25%). Debris deposits on the intaglio surface of the prosthesis, especially at the margins, was not a reported problem, while this remains a common finding in adhesive retained auricular prostheses. The overall success rate of osseointegration remains higher than that of long term prosthesis stability for implant retained auricular prostheses. Both Nishimura⁹ and Wright¹¹ reported 100% success rates for osseointegration of auricular implants, with no losses of implant fixtures.

Conclusions

As evidenced by the functional and esthetic success of auricular implants reported in the literature and in this case report, the application of Branemark's original design has made great strides in the rehabilitation of a variety of fea-

tures of the craniofacial skeleton in addition to the dento-alveolar structures. Osseointegrated temporomastoid implant fixtures are an effective way to attach and retain an auricular prosthesis, provided that the patient selected is healthy enough to withstand surgery and has adequate quality and quantity of bone at the implant site. Possible complications of surgery are limited and usually have no lasting deleterious effects. Adherence to established surgical and prosthetic protocols allows for equal distribution of functional loading forces among the implants used to retain either a magnet-based or bar-and-clip retentive framework. The patient must maintain a hygienic environment around the healing abutments in order to minimize soft tissue overgrowth and irritation. While temporal implants display the most reliable record of successful osseointegration when compared to orbital and nasal implants, the attached prostheses themselves are still subject to traumatic forces and discoloration and will most likely need to be replaced more than once during the lifetime of the patient. Successful fabrication of an implant-supported auricular prosthesis requires interdisciplinary collaboration between the oral surgeon, maxillofacial prosthetist and anaplastologist.

References

1. Asher ES, Evans JH, Wright RF, Wazen JJ. "Fabrication and use of a surgical template for placing implants to retain an auricular prosthesis." *The Journal of Prosthetic Dentistry* 81.2 (1999): 228-233.
2. Branemark PI, Hansson BO et al. "Osseointegrated implants in the treatment of the edentulous jaw. Experience from a 10-year period." *Scandinavian Journal of Plastic & Reconstructive Surgery* 16.1 (1977): 1-132.
3. Chung RWC, Siu ASC, Chu FCS, Chow TW. "Magnet-retained auricular prosthesis with an implant-supported composite bar: A clinical report." *The Journal of Prosthetic Dentistry* 89.5 (2003): 446-449.
4. Goiato MC, Delben JA, Monteiro DR, dos Santos DM. "Retention Systems to Implant-Supported Craniofacial Prostheses." *The Journal of Craniofacial Surgery* 20.3 (2009): 889-891.
5. Gumieiro EH, Dib LL, Jahn RS, Ferreira dos Santos J, Nannmark U, Granstrom G, Abrahao M. "Bone-anchored titanium implants for auricular rehabilitation: case report and review of literature." *Sao Paulo Medical Journal* 127.3 (2009): 160-165.
6. Karakoca S, Aydin C, Yilmaz H, Bal BT. "Retrospective study of treatment outcomes with implant-retained extraoral prostheses: survival rates and prosthetic complications." *The Journal of Prosthetic Dentistry* 103.2 (2010): 118-126.

Successful Osseointegration and Prosthetic Loading of a Temporomastoid Implant in the Treatment of Congenital Hemi-Anotia: A Case Presentation

7. Miles BA, Sinn DP and Gion GG. "Experience with Cranial Implant-Based Prosthetic Reconstruction." *The Journal of Craniofacial Surgery* 17.5 (2006): 889-897.
8. Nakamura, Yuko C. Personal Communication 2/2010
9. Nishimura RD, Roumanas E, Sugai T, Moy PK. "Auricular prostheses and osseointegrated implants: UCLA experience." *The Journal of Prosthetic Dentistry* 73.6 (1995): 553-558.
10. Wilkes GH, Wolfaardt JF. "Osseointegrated Alloplastic vs Autogenous Ear Reconstruction: Criteria for Treatment Selection." *Plast Reconstr Surg* 93.5 (1994): 967-979.
11. Wright RF, Zemnick C, Wazen JJ, Asher E. "Osseointegrated Implants and Auricular Defects: A Case Series Study." *The Journal of Prosthodontics* 17 (2008): 468-475.

Treating a Vertically Deficient Edentulous Maxilla with Onlay Bone Grafts and a Maxillary Overdenture

Paul Jones Jr¹, Ray Jone DDS², Jason J. Psillakis DDS, MS³

¹Class of 2012, College of Dental Medicine, Columbia University, New York, NY

²General Practice Resident, San Francisco V.A. Hospital, San Francisco, CA

³Assistant Professor of Clinical Dentistry, Division of Prosthodontics, Columbia University College of Dental Medicine, New York, NY

Abstract

The edentulous atrophic maxilla poses several difficulties to prosthodontic rehabilitation. In the case presented here, reconstructive pre-prosthetic surgery with onlay bone block grafts was performed with subsequent implant placement after a delayed healing period. Bone grafts were harvested from the iliac crest. Five of seven implant fixtures integrated successfully. The patient was successfully rehabilitated with an implant-supported overdenture. Implants were splinted using a milled bar with ERA attachments cantilevered distally.

Introduction

The edentulous atrophic maxilla poses several difficulties to prosthodontic rehabilitation. Within the first year of edentulism, a patient's alveolar ridge can drastically change shape in both horizontal and vertical axes. The common progression outlined by Cawood follows from dentate (class 1), to immediate post-extraction (class 2), to an ideal well-rounded ridge form (class 3), to a narrower knife-edge ridge (class 4), to a flat ridge form (class 5), and ultimately to the worst-case scenario of a depressed ridge form involving the basilar bone level (class 6).¹

Alongside the morphologic changes to the alveolar ridge is the loss of key anatomic features needed to support a functional prosthesis including bone height, a class 1 maxillary-mandibular relationship, and ideal muscle attachments. The advent of dental implants has increased the success rate with which partially and fully edentulous patients with non-ideal bone structure can be rehabilitated. Placement of dental implants has become a common practice and there is an increasing amount of reliable data to support their utilization. While higher success rates are attributed to the length of dental implants, an alveolar ridge with a large vertical deficit reduces the success rate of dental implants due to insufficient bone volume housing the fixtures.^{2,4}

Patients with insufficient bone volume require reconstructive pre-prosthetic surgery to increase the bone volume and create an oral environment that allows the accompanying prosthesis to restore function to the patient. A successful prosthesis should be stable and retentive, preserve existing tissues and satisfy the patient's esthetic demands. According to evidence-based literature, current forms of treatment

to increase bone volume are onlay bone grafts³, nasal floor and sinus augmentation⁴, and interpositional graft with Le Fort 1 osteotomy⁵. Onlay bone grafts and interpositional graft with a Le Fort 1 osteotomy are the most commonly used methods, as they produce clinically acceptable results and do not significantly decrease implant survival rates.^{6,7} This case study presents a patient with an edentulous atrophic maxilla that was restored in a two-stage approach. First, the alveolar ridge was augmented with onlay bone block grafts harvested from the iliac crest. Second, implants were placed following an extended healing period.

Case Report

A 46-year old female patient presented to the Columbia-Presbyterian Eastside Dental Faculty Practice with the following chief complaint, "I want teeth to chew, eat, smile, and speak." A complete prosthodontic workup was done, which included radiographs, mounted diagnostic casts, and a review of the remaining teeth and surrounding soft tissues.

The patient presented with a severely resorbed, atrophic edentulous maxilla. The mandible had bilateral edentulous spans, with only #22-27 remaining. (*Figure 1*) Various treatment plans were discussed with the patient for the maxilla, including a complete denture and the possibility of implants. Since the maxilla was severely resorbed and flat, a maxillary complete denture would have a poor prognosis due

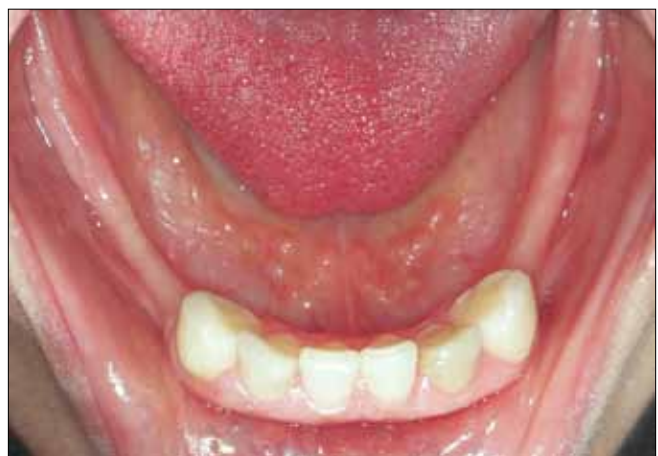

Figure 1 Occlusal view of mandible at initial presentation

Treating a Vertically Deficient Edentulous Maxilla with Onlay Bone Grafts and a Maxillary Overdenture

to insufficient retention, stability and function. Implants in conjunction with maxillary bone grafts were mentioned to the patient. It was explained that the graft would be necessary to augment the quantity of bone available for implant placement and to restore lost facial features, such as cheek and lip support, which had also collapsed due to atrophy. The patient consented and agreed to receive bone grafts and the implants.

The patient underwent pre-prosthetic surgery of the edentulous maxilla with bilateral onlay bone grafts from the iliac crest. This was followed by a two-stage approach for implant fixture placement more than six months after the initial bone graft procedure. The patient had a Cawood class 5 edentulous maxilla that necessitated a large volume of grafted bone to provide sufficient height for implant fixture placement. Five implants were initially placed into the maxilla with the treatment goal of making an overdenture. During stage 2 uncovering of the fixtures, two implants failed and were removed.

The failed sites were allowed to heal naturally and were re-evaluated in six months. Upon reevaluation, two new implant fixtures were placed which did eventually osseointegrate.

After the fixtures were uncovered and healing abutments were placed, new diagnostic cast were made and custom trays were fabricated for a fixture-level final impression. Wax records were made, the cast was mounted, and wax teeth try in was completed with the patient's approval for processing. During treatment, it was decided to splint the implants together with a gold bar since two fixtures had previously failed, and an open palate overdenture design was selected to restore facial contours and esthetics while allowing better speech. (Figure 2,3) The opposing arch was restored with a conventional distal extension removable partial denture. (Figure 4,5) The case was processed, completed, and delivered to the patient's satisfaction. (Figure 6,7) Only one post-op adjustment was necessary to adjust a sore spot noted on the mandibular prosthesis.

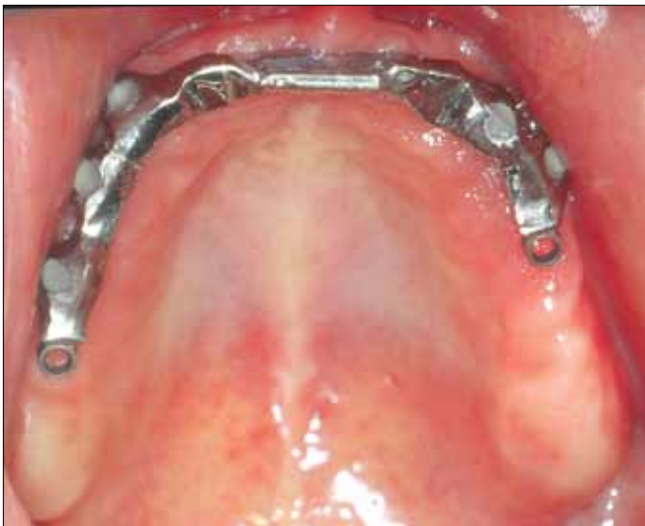

Figure 2 Palatal view of maxilla with splinted bar with ERA attachments

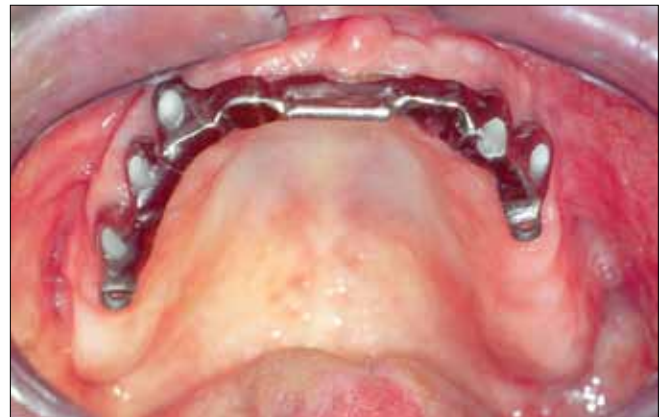

Figure 3 Frontal view of maxilla with splinted bar with ERA attachments

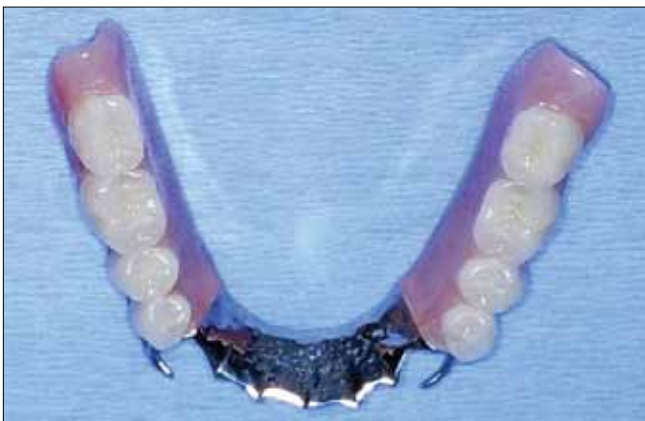

Figure 4 Occlusal view of mandibular RPD

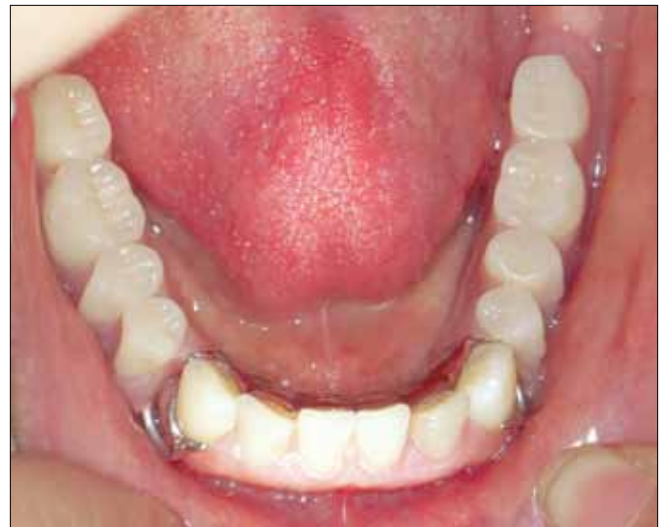

Figure 5 Occlusal view of seated mandibular RPD

Treating a Vertically Deficient Edentulous Maxilla with Onlay Bone Grafts and a Maxillary Overdenture

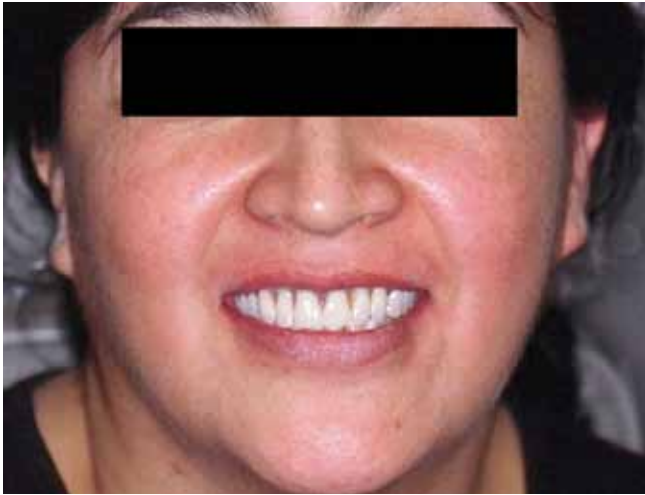

Figure 6 Esthetic photograph showing patient smiling while wearing maxillary prosthesis

Discussion

As described by Cawood and Howell, there are various formations of the edentulous atrophic maxilla posing difficulty for its rehabilitation. In many cases, pre-prosthetic surgery is necessary to augment the maxillary ridge and provide sufficient volume of bone for rehabilitation, especially if an implant-supported prosthesis is planned.¹ As Nystrom and Nilson reviewed (2009), patients who develop a class VI resorption pattern and a poor intermaxillary relationship would benefit most from a Le Fort 1 osteotomy in parallel with an interpositional bone graft and a 4-6 month interval of healing prior to implant placement.^{5,11} However, patients presenting with a class V resorption pattern and acceptable intermaxillary relationship do not require forward re-positioning by a Le Fort 1 osteotomy and would benefit most from an onlay bone block graft. Such a procedure offers the largest volume of bone that can be recouped. However, it should be noted that the graft design has not been shown to affect implant survival rates.⁸

In this case, the iliac crest was chosen as the donor site. The iliac crest offers the greatest amount of corticated bone, the quantity of which determines the amount of graft that is resorbed as well as the quality of bone that remains for implant placement. Larger quantities of corticated bone leads to higher success rates for implant survival.⁹ A two-stage implant approach was chosen in lieu of a one-stage, which would have entailed simultaneous graft and implant placement. While the one-stage procedure does offer the benefit of less surgical intervention and decreased healing time, a two-stage procedure has been shown to be more successful because the graft has integrated; thus placement and angulation of the implant are better controlled.^{5,8} A review of the literature reveals that implant survival is higher when a two-stage approach is attempted (88%) as opposed to a single-stage approach (79%).¹⁰

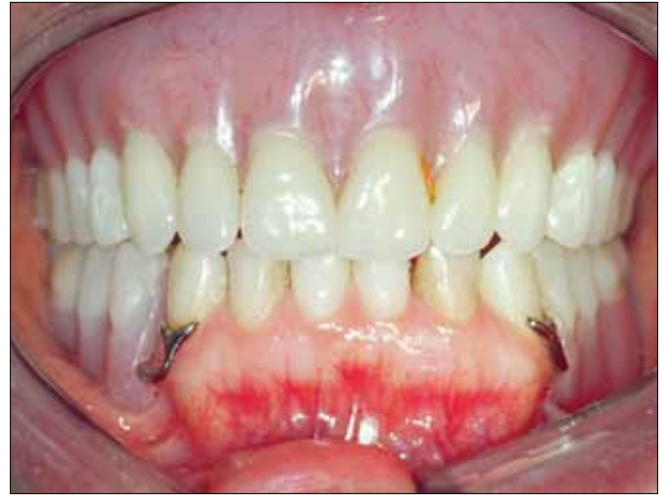

Figure 7 Frontal view of patient in maximum intercuspation while wearing maxillary overdenture and mandibular RPD

A principal factor of concern when treating an atrophic maxilla with an onlay bone graft is the duration for which bone resorption occurs. Although grafts require six months to take to the site prior to initiating implant therapy, bone resorption continues to occur for 12 months following graft placement.¹¹ Thus grafted bone may still be undergoing re-modeling processes for an additional six months after implant placement. It is well documented that loss of ridge height can range from 20% to 31% at one year to 44% to 92% at three years.¹¹ Despite early bone loss, implant placement has also been shown to guard against bone resorption, due to the molecular signals initiated by loading feedback through the alveolar bone. Therefore, the possibility for initial resorption must be balanced by long-term stability for the case to be successful. In the case presented here, implants were not placed until over a year after the graft.

Five implants were initially placed as dictated by the patient's finances and the established recommendations by Eckert and Carr.¹² While a minimum of four implants is recommended for a favorable outcome, a higher number of implants allows for the potential failure of one to two implants while still maintaining the minimum number of implants for a successful prosthesis. Thus Eckert and Carr proposed the minimum limit to be six implants. Five implants were placed because maxillary implant overdentures have been documented to have a high implant loss relative to other treatment modalities.^{7,12} Over the course of six years, Narhi et al. reported a cumulative 90% implant survival.¹² Thus in the worst case scenario that one implant is lost during osseointegration or over the long-term, there are still sufficient implants for long-term success of an overdenture. Replacing the two failed implants in this case satisfies the minimum of four implants needed for a favorable outcome, while also compensating for the failure of one implant in the future.

Treating a Vertically Deficient Edentulous Maxilla with Onlay Bone Grafts and a Maxillary Overdenture

In this case, the implant survival rate after one year was 71.4%. There remains substantial variability in the predicted survival rates reported in the literature. In a 3-year longitudinal study, Astrand and Branemark reported an implant-in-graft survival rate of 75%, while Sjostrom and Sennerby reported implant-in-graft survivals of 90% at a 3-year follow up.^{13,8} The literature regarding failure rates and factors causing implant-in-graft failure remains controversial.

The role of patient gender in implant-in-graft survivals has been shown by Sjostrom to be a statistically significant variable (14% female fail rate, 3% male fail rate) while Laverick and Cawood found no statistical difference in the survival of implants placed in male and female patients.⁶

The reported timing of failed osseointegration in the literature is also not consistent. In the case presented, the two failures occurred prior to loading the implants. Esposito and Hirsch, along with Barone and Covani reported a higher rate of failure occurring prior to loading. Astrand and Branemark in their 1996 three-year longitudinal study reported contrasting data: 7 of 23 failures occurred prior to loading while 16 of 23 failures occurred after loading.^{14,15}

While further data relating implant survival to other variables needs to be gathered, Sjostrom brings up an interesting point: multiple implant failures are not uniformly distributed in a pool of patients but rather clustered around specific patients.⁸ In Sjostrom's 2007 article, while seven of ten patients lost one to two implants (not affecting the supra-structure of the overlying prosthesis), one patient lost five implants, accounting for close to half of the failures in their study. Similar distributions were reported by Lekholm and Johansson in separate studies. This could suggest a need for more research tailored to address patient factors that affect the local environment in which implants osseointegrate, as most literature has focused on characteristics of the implants themselves and the manner in which they are placed in relation to their success. Indeed it is the catastrophic loss of multiple implants in a single patient that threatens the long-term rehabilitation, rather than individual implant failure. In the case presented, implant sites that failed were allowed to heal naturally before replacing the implants lost.

For the design of the prosthesis, a milled-splinted bar was utilized as the understructure for the maxillary overdenture with two ERA attachments cantilevered distally. (Figure 8) Unsplinted anchorage designs require less space between the implant platform and the incisal edge, may be more hygienic, and are less technique sensitive to place.¹² However, splinted designs have been shown both in vivo and in vitro to provide more retention than unsplinted designs when subjected to vertical and oblique forces. Splinted designs also allow for correction of implant abutment angulations if

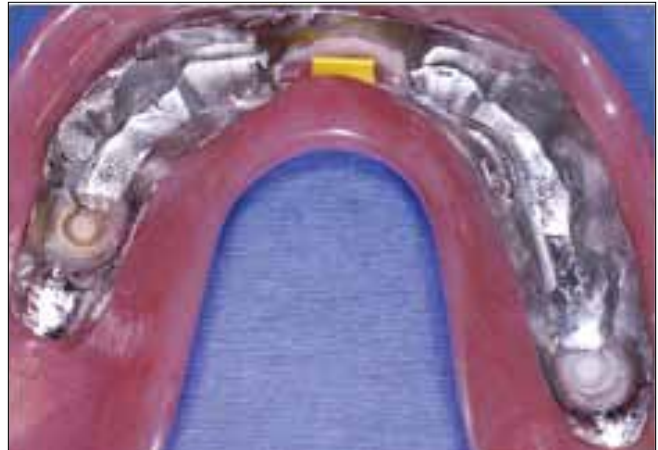

Figure 8 Close up image of maxillary overdenture understructure showing clip and distal ERA attachments

needed.¹² Thus a splinted design was utilized to maximize retention given that the implants were placed in grafted tissue and a palateless design was chosen to maximize patient comfort. (Figure 9,10) A milled bar was utilized because

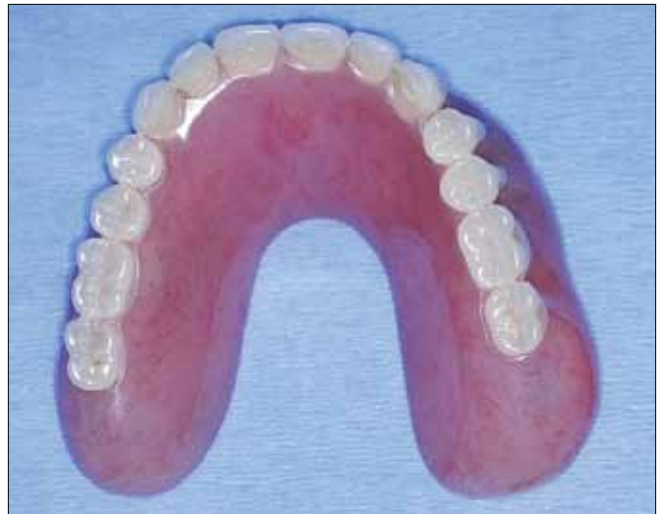

Figure 9 Cameo view of U-shaped palate-less maxillary overdenture

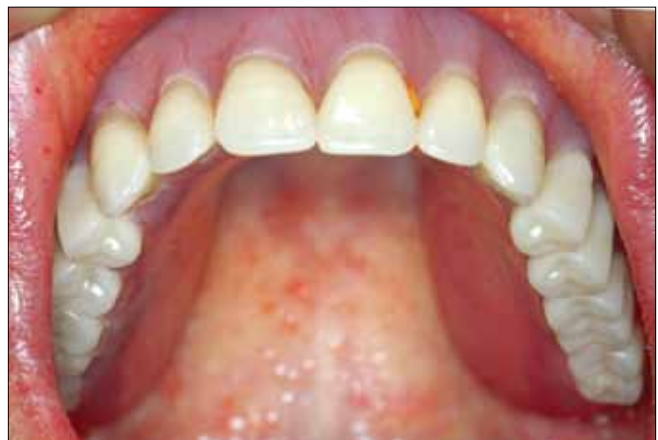

Figure 10 Palatal reflection of seated maxillary overdenture

Treating a Vertically Deficient Edentulous Maxilla with Onlay Bone Grafts and a Maxillary Overdenture

a relatively high number of non-symmetrical implants were to be connected. Distally placed ERA attachments have also been shown to increase retention of bar overdentures and thus were included in the design as well.¹² However, it should be noted that bars with distal cantilevers tend to increase the load on the terminal implants by a factor of greater than three.¹²

Conclusion

This article describes the management and treatment rationale for rehabilitating a patient with an atrophic edentulous maxilla. The treatment protocol of using an onlay bone graft harvested from the iliac crest and an implant-supported overdenture successfully restored the patient to function. In this case, five out of seven implant fixtures achieved integration to maintaining a minimum number of implants for a favorable prognosis. Overdentures with a milled bar and ERA attachments provided stability for a palateless design to maximize comfort and function.

References

1. Cawood JI, Howell RA (1988) A classification of the edentulous jaws. *Int J Oral Maxillofac Surg* 17: 232.
2. Chiapasco M, Zaniboni M, Rimondini L (2007) Autogenous onlay bone grafts vs. alveolar distraction osteogenesis for the correction of vertically deficient edentulous ridges: a 2-4 year prospective study on humans. *Clin Oral Impl Res* 18: 400- 432.
3. Nystrom E, Ahlqvist J, Legrell PE, Khanberg KE (2002) Bone graft remodeling and implant success rate in the treatment of the severely resorbed maxilla: a 5-year longitudinal study. *Int J Oral Maxillofac Surg* 31: 158-164
4. Lundgren S, Nystrom E, Nilson H, Gunne J, Lindhagan O (1997) Bone grafting to the maxillary sinuses, nasal floor and anterior maxilla in the atrophic edentulous maxilla: a two-stage technique. *Int J Oral Maxillofac Surg* 26: 428-434
5. Nystrom E, Lundgren S, Gunne J, Nilson H (1997) Interpositional bone grafting and Le fort 1 osteotomy for reconstruction of the atrophic edentulous maxilla: a two-stage technique. *Int J Oral Maxillofac Surg* 327- 423*****
6. Laverick S, Summerwill J, Cawood JI (2008) Ten years of experience with the anterior maxillary and mandibular osteoplasty (class IV ridges): a retrospective analysis of implant survival rates. *Int J Oral Maxillofac Surg* 37: 415-418
7. Clayman C (2006) Implant reconstruction of the bone-grafted maxilla: review of the literature and presentation of 8 cases. *J Oral Maxillofac Surg* 64: 674-682
8. Sjostrom M, Sennerby L, Nilson H, Lundgren S (2007) Reconstruction of the atrophic edentulous maxilla with free iliac crest grafts and implants: a 3-year report of a prospective clinical study. *Clin Implant Dent Relat Res* 9(1):46-59
9. Isaksson S, Alberius P (1992) Maxillary alveolar ridge augmentation with onlay-bone grafts and immediate endosseous implant *J of Cranio-Maxillo-facial Surgery* 20: 2-7
10. Blomqvist JE, Alberius P, Isaksson S (1997) Sinus inlay bone augmentation: comparison of implant positioning after one or two-staged procedures. *J Oral Maxillofac Surg* 55(8): 804-810
11. Nystrom E, Ahlqvist J, Gunne J, Johnberg KE (2004) 10-year follow up on onlay bone grafts and implants in severely resorbed maxillae. *Int J Oral Maxillofac Surg* 33: 258-262
12. Sadowsky S (1997) Treatment considerations for maxillary implant overdentures: a systematic review/ *J Prosthet Dent* 97(6): 340-348
13. Astrand P, Nord PG, Branemark PI (1996) Titanium implants and onlay bone graft to the atrophic edentulous maxilla: a 3 year longitudinal study. *Int J Oral Maxillofac Surg* 25: 25-29
14. Esposito M, Hirsch JM, Lekholm U, et al (1998) Biological factors contributing to failures of osseointegrated oral implants: success criteria and epidemiology. *Eur J Oral Sci* 106: 527
15. Barone A, Covant U (2007) Maxillary alveolar ridge reconstruction with nonvascularized autogenous block bone: clinical results. *J Oral Maxillofac Surg* 65: 2039-2046

The Columbia Dental Review seeks to address topics of clinical concern. The Editorial Board welcomes articles from students, faculty, and attendings from affiliated hospitals of the College of Dental Medicine of Columbia University.

The case report should be organized in the following manner:

Abstract

The abstract summarizes the principal points of the case report and specific conclusions that may have emerged in the discussion. It should be limited to less than 250 words.

Author Information

A description of each author's degrees, titles, department, and affiliation should be given.

Introduction

The introduction should provide a brief description of the topic, as well as any relevant epidemiology and current opinion as documented in the literature.

Case Report

A description of the case(s), including pertinent photographs.

Discussion

A thorough review of the literature, including other reported cases that are relevant to the case(s) presented or reported.

Conclusion

Based on the present case(s) and the discussion.

References

The authors should be listed in the order in which they appear in the articles. In the case of multiple authors, all authors' names must be given.

Within the text citations of these references should appear as follows:

(Valverde et al, 2005), (Cowin and Luo, 1997), and (Drake et al, 2005), or (Valverde et al, Cowin and Luo, Drake et al 1,2,3)

To cite a journal article:

Valverde P, Kawai T, Taubman MA (2005) Potassium channel-blockers as therapeutic agents to interfere with bone resorption of periodontal disease. J Dent Res 84: 488-499.

To cite a chapter in a book:

Cowin SC, Luo G (1997) Modeling of ingrowth into implant cavities along the bone implant surface. In: Osseointegration in Skeletal Reconstruction and Joint Replacement (PI Brånemark, BL Rydevik, R Skalak, Eds) Chicago, Quintessence Publishing Co, Inc, pp 57-72.

To cite a book:

Drake RL, Vogl W, Mitchell AWM (2005) Gray's Anatomy for Students. Philadelphia, Elsevier.

To cite a website:

American Dental Association. Estrogenic effects of Bisphenol A lacking in dental sealants. ADA Position Statement. 2000. Available at: "www.ada.org/prac/position/ seal-est.html". Accessed April 4, 2005.

Figures and Manuscripts

Image files and manuscripts will be accepted on CD with author's name printed on the CD. Image files should be of high-resolution quality and should be submitted in TIFF, TIF, TGA, GIF or JPEG format. A brief caption in the order in which they are mentioned should be submitted on a separate page. The manuscript should not exceed 20, letter size, double-spaced pages and should be written in a text editor, preferably Microsoft® Office Word. Both, the manuscript and figures, should be submitted in printed format as well as on CD.

