

Traumatic Bone Cyst in a Child: A Case Report

Gloria Lee, DDS¹, Katrin Tamari, DDS²

¹Advanced Education in General Dentistry Resident, College of Dental Medicine, Columbia University, New York, NY

²Assistant Professor of Dental Medicine, College of Dental Medicine, Columbia University, New York, NY

Abstract

Traumatic bone cyst (TBC) is a relatively common non-odontogenic primary bone lesion that may involve jaw. Although designated as a 'cyst', this lesion represents an empty cavity within the bone, hence is a pseudocyst rather than a true cyst. TBC presents as a well-defined unilocular radiolucency resembling odontogenic cyst, thereby posing a diagnostic challenge to dentists.¹ In this paper, we present a case of TBC in a 14-year-old child. We also explore the diagnostic work-up and treatment of the lesion.

Introduction

Non-odontogenic primary bone lesions are uncommon in the jaws of both adult and pediatric patient population compared to those that are odontogenic in origin. Traumatic bone cyst is primary bone lesion seen in the jaw and is also known as solitary bone cyst, hemorrhagic bone cyst, extravasation cyst and simple bone cyst, progressive bone cavity, unicameral bone cyst, and idiopathic bone cavity.^{1,2} The etiopathogenesis of TBC is unknown. One theory is that trauma to the jaw results in an intraosseous hematoma formation. If the hematoma fails to undergo organization and repair, it may liquefy, thereby resulting in an empty or fluid-containing bone cavity.¹ Other theories include abnormal growth or metabolism of the local jawbone, tumor degeneration, alteration in calcium metabolism, mild infection, orthodontic treatment, and venous obstruction.³

Traumatic bone cyst is found in almost all bones of the body, mostly in the proximal humerus and femur. Pathologic fractures are commonly associated with this lesion in long bones. In the jaw, it is most commonly found in the posterior mandible, with rare occurrences in anterior maxillary bone, ramus, zygoma, coronoid process, and condyle.³ There is no gender predilection for this lesion.¹ The lesion is most frequently found in patients in their second and third decades of life.¹ As there is no epithelial lining of the cyst, the traumatic bone cyst is considered a pseudocyst rather than a true cyst. TBC is rarely associated with tooth resorption, although larger lesions may cause displacement of teeth and painless bone expansion. Traumatic bone cyst is mostly found as unilocular lesion, but sometimes as multilocular or lobular lesion.³

Diagnosis of traumatic bone cyst is based on clinical, radiographic, and intraoperative findings. During surgical exploration, either an empty cavity or a cavity containing small amount of fluid is discovered, which is diagnostic of traumatic bone cyst. The bony wall of TBC is curetted to obtain small amount of tissue to rule out other pathology. Curettage of the bony wall initiates bleeding, which in turn lead to new bone formation. If the lesion is indeed a

traumatic bone cyst, any tissue obtainable for histopathological analysis will confirm its diagnosis along with absence of epithelial lining observed upon surgical exploration.⁴ However, histopathological analysis may not always be possible as there may be no or scant amount of material for the examination. Therefore, definite diagnosis of traumatic bone cyst is mostly achieved upon surgical treatment.⁵ Complete healing is expected to occur in up to two years, while initial stages of healing can be observed within three to six months of the surgery. As recurrence of this lesion has been reported to be from 2% to 26%, radiographic and clinical follow-up is recommended.³

Case Report

A 12-year-old male initially presented to the clinic in 2013 for routine dental care with his mother. The patient had unremarkable medical history and had no known drug allergies. Extraoral examination was negative for swelling and cervical or submandibular lymphadenopathy. Intraoral findings were non-contributory; 28 reasonably well-aligned permanent, non-restored and non-carious teeth with mild plaque accumulations and Class I occlusion.

In 2015, the patient returned to clinic with his mother for a routine dental care. A panoramic radiograph and bitewings were taken, which revealed a radiolucent partly corticated unilocular lesion in the lower mandible at the apices of teeth #22 to #28 (Figure 1). The patient and his mother denied observing any symptoms associated with the lesion and stated that they did not know about the lesion previously. Extraoral examinations again were unremarkable, with no swelling observed. Intraoral examination showed no bone expansion associated with the lesion. A periapical radiograph was taken in order to evaluate the periapical radiolucency in more detail (Figure 2).

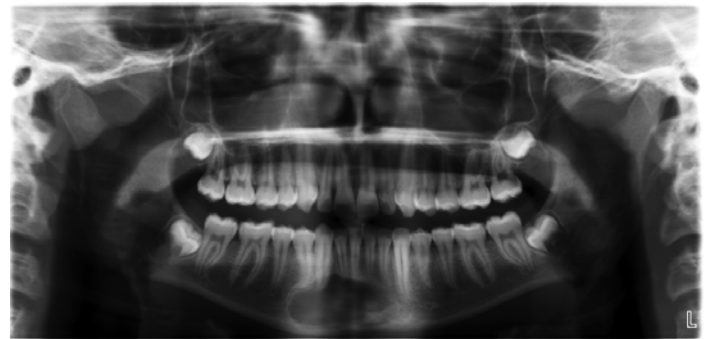

Figure 1 Panoramic radiograph allowed incidental finding of the periapical radiolucency involving apices of teeth #22-#28.

Placement of Glass Ionomer as an Interproximal Sealant: A Case Report

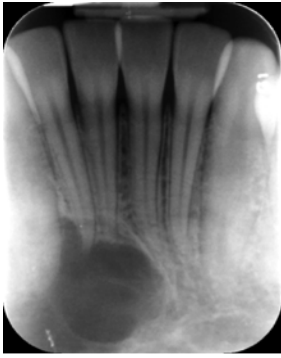


Figure 2 Periapical intraoral radiograph was taken in order to evaluate the periapical radiolucency in greater detail.

The patient was referred to the Oral and Maxillofacial Surgery clinic for further evaluation and treatment. Bone biopsy under local anesthesia was performed. Three carpules of 2% lidocaine with 1:100k epinephrine was used to achieve local anesthesia. Incision was made in the unattached buccal gingiva of teeth #25 to #27 with full thickness of 1.5 centimeters. Dissection was made to find the cortex of the lesion, and bony window was created with saber. Curettage of the cyst was performed. Surgical exploration revealed that there was no epithelial lining in the lesion, and no material was recovered for biopsy. With hemostasis achieved, the incision site was closed with 3-0 chromic gut suture. The patient was dismissed in stable condition.

Discussion

From the panoramic radiograph the lesion was observed to be a partly corticated radiolucency in the anterior mandible extending from mesial of tooth #22 to distal of #28. The border extended from inferior border of the mandible to apices of lower anterior teeth. Periapical radiograph showed that the lesion was observed to be scalloped and crossing the midline. Because all teeth (#22-#28) overlying the lesion were vital, periapical pathologies, such as periapical granuloma and radicular cyst, were ruled out.

For treatment of the lesion, due to the possibility of the lesion being a vascular one, auscultation and palpation of the lesion are recommended, followed by aspiration with 15 gauge needle prior to surgical exploration. In a child, a possible reason for concern is a vascular malformation, which is ruled out when aspiration does not draw any blood. Other differential diagnosis included central giant cell granuloma and ameloblastoma for anterior regions of the mandible, keratocystic odontogenic tumor, which could also occur in the anterior mandible, and traumatic bone cyst that could also occur anywhere further posteriorly in the body of the mandible. Due to the size of the lesion, surgical exploration was performed followed by curettage. The diagnosis of traumatic bone cyst was rendered by the

surgical exploration revealing an empty cavity and also by the microscopic examination of the curetted cavity wall confirming absence of epithelial lining. For TBC, a radiographic follow up is recommended three to six months following the curettage.

Although rare, a simple bone cyst can demonstrate aggressive clinical behavior raising a concern for malignancy. There has been a report on an aggressive simple bone cyst that caused pain on left mandibular area for two months and eventually lead to paresthesia of the lower lip. The cone beam computed tomography scan showed that the lesion had rapidly enlarged over time and destroyed the upper cortical border of the left mandibular canal and perforated buccal and lingual cortex. The surgical exploration and microscopic examination of curetted specimen confirmed the diagnosis of traumatic bone cyst in this case.⁶

Alternative to curettage of the bone cavity was introduced in literature, which involves “application of Gelfoam, grafting of allogenic bone with platelet-rich plasma and intralesional injections of a mixture of blood, porous hydroxyapatite, and bone fragments.”⁷ This grafting procedure was reported to produce good results, although other studies questioned efficacy of such treatment.³ Spontaneous resolution of the lesion has also been reported. However, as some of TBCs may exhibit rapid and aggressive growth, simple observation is not recommended.

Conclusion

Despite the relatively low occurrence of non-odontogenic primary bone lesions in the jaw, clinicians should consider all possibilities when formulating differential diagnosis. It is also pertinent to understand the clinical characteristics and management of traumatic bone cyst in order to reduce patient morbidity. As there is a possibility of this lesion enlarging to result in bone expansion and destruction, surgical exploration and curettage is an important step not only for proper treatment, but also for rendering diagnosis and ruling out malignant lesions.

References

1. Kumar ND, Sherubin JE, Raman U, Shettar S (2011) Solitary bone cyst. *Indian Journal of Dental Research* 22(1): 172-174.
2. Kumar S, Padmashree S, Rema J (2014) Traumatic Bone Cyst of Idiopathic Origin? A Report of Two Cases. *Ethiop J Health Sci* 24(2): 183-187.
3. Findik Y, Baykul T, Bulte M (2014) Huge Solitary Bone Cyst located in Posterior Mandible. *International Journal of Experimental Dental Science* 3(1): 53-56.
4. Shah KM, Mistry JD (2013) Traumatic bone cyst or

Placement of Glass Ionomer as an Interproximal Sealant: A Case Report

solitary bone cyst. BMJ Case Rep.
doi:10.1136/bcr-2013-008998

5. Bulut E, Bas B, Dincer D, Gunhan O (2016) Treatment of Maxillary Glandular Odontogenic Cyst Involving the Same Place of Previously Treated Traumatic Bone Cyst. The Journal of Craniofacial Surgery 27(2): e150-e153. Doi: 10.1097/SCS.0000000000002396.

6. Nikneshan S, Hadian H (2015) Unusual Aggressive Radiographic Appearance of Simple Bone Cyst (A Case Report and Review of Literature). British Journal of Medicine & Medical Research 6(8): 833-840.

7. An S, Lee J, Benavides E, Aminlari A, McDonald NJ, Edwards PC, Heo M, Shin H, Park J, Jung J, Choi K, An C (2014) Multiple simple bone cysts of the Jaws: Review of the literature and report of three cases. Oral Surg Oral Med Oral Pathol Oral Radiol 117: e458-e469.

Treatment of an Adult Unilateral Complete Cleft Lip and Palate Patient: A Case Report

Keith Jaffe Goldman, DMD, MS¹, Jing Chen, DDS, PhD²

¹Orthodontic Resident, Section of Growth and Development, College of Dental Medicine, Columbia University, New York, NY

²Assistant Professor of Dental Medicine, Section of Growth and Development, Division of Orthodontics, College of Dental Medicine, Columbia University, New York, NY

Abstract

The most common congenital defect involving the face and the jaws is clefting of the lip and/or the palate. Treatment of a cleft lip/palate patient often requires many stages of treatment that generally begin at an early age and continue until the patient is a young adult. Two common complexities that these patients face are with regard to the maxillo-mandibular relationships and the dentition. This case report examines a young adult patient with a unilateral complete cleft lip and palate that was undergoing combined orthodontic and surgical treatment. This article specifically chronicles the orthodontic and surgical treatment completed prior to orthognathic surgery. The treatment successfully addressed transverse, Anterior-Posterior (A-P), and vertical dimensions with a combined surgical and orthodontic intervention.

Introduction

The most common congenital defect involving the face and the jaws is clefting of the lip and/or the palate. Clefts generally develop between the fourth and sixth weeks of the embryonic period.¹ Cleft lips occur because the median and lateral nasal processes fail to fuse with the maxillary process. Notching of the alveolar process often accompanies a cleft lip since the lip and alveolar process initially are not separate structures at the time of primary palate development. Consequently a failure of fusion may affect both. About 60% of patients with a cleft lip also present with clefting of the palate as interference with lip closure can hinder the fusion of the palatal shelves. This fusion is the process that closes the secondary palate.^{2,3,4} Cleft palates can be classified as unilateral or bilateral and can either be complete or incomplete. A complete cleft of the palate involves the length of both the primary and secondary palate. In contrast, an incomplete cleft involves only the secondary palate.⁵

Treatment of a cleft lip/palate patient often requires many stages of treatment that generally begin at an early age and continue until the patient is a young adult. It is common that many different medical specialists are involved in the process over many years and must often work in congruence for successful treatment of patients with these particular conditions.

Two common complexities that these patients face are with regard to the maxillo-mandibular relationships and the dentition. Thus the role of the maxillofacial surgeon and the orthodontist are of the utmost importance in improving the

quality of life of patients who experience one of these conditions. This case report examines a young adult patient with a unilateral complete cleft lip and palate that was undergoing combined orthodontic and surgical treatment. This article specifically chronicles the orthodontic and surgical treatment completed prior to orthognathic surgery.

Diagnosis

A 19-year-old adult male presented to the Columbia University CDM Orthodontic department with the chief complaint of "I have crooked teeth" (Figure 1). The patient's medical history was significant for anxiety, PTSD, and complete cleft lip and palate on the left side. No history of any habits were reported. The patient's past dental history revealed limited dental care throughout the patient's childhood. The patient's TMJ had normal range of motion, and no joint noises were noted.

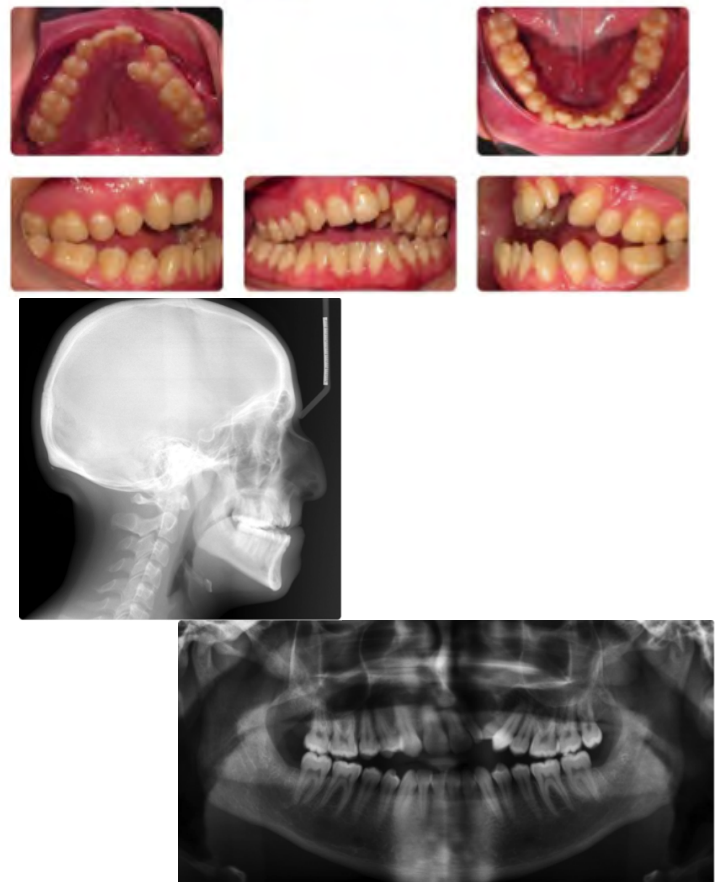


Figure 1 Initial intra- and extra-oral records, panoramic radiograph, and lateral cephalometric radiograph

Treatment of an Adult Unilateral Complete Cleft Lip and Palate Patient: A Case Report

Intra-oral examination and cephalometric evaluation (Figure 1, Table 1) showed the patient had a Class I skeletal base with a bimaxillary retrognathia and a transverse maxillary deficiency. He had an Angle Class II Division 1 dental malocclusion, however a 5mm negative overjet. The patient had a vertical growth pattern, and an open bite from right first molar to left first molar, being 7mm at its worst point. The upper and lower incisors were excessively upright; both arches being of the tapered form. The patient's upper right lateral incisor was congenitally missing, and he had an upper left peg-lateral incisor. There was a fistula between the patient's upper left lateral incisor and cuspid as a result of a palatal cleft that had never received a bone or tissue graft. He had moderate upper and lower crowding with an ectopically erupted upper left first bicuspid. There was a significant maxillary cant present. Facially the patient had a retrognathic soft tissue profile, poor upper lip support, mentalis strain on lip closure, uneven incisor display on smile, non-consonant smile arc, and non-coincident midlines. The congenital developmental deficiency was diagnosed as the major etiological factor for this patient.

Table 1: Cephalometric Data

	Pre- Treatment	Pre-Surgical
SNA	77°	77°
SNB	75°	76°
ANB	3°	2°
SN-MP	42°	43°
U1-SN	81°	88°
L1-MP	85°	88°

Table 1 Pre-treatment and pre-surgical cephalometric measurements

Treatment Plan

The objectives of treatment for this patient were to improve transverse, Anterior-Posterior (A-P), and vertical dimensions with a combined surgical and orthodontic intervention. In doing so we hoped to achieve Class I molar and Class III canine pre-surgically with the upper right canine substituting for the missing lateral and thus the upper right first bicuspid serving as the upper right canine (to be corrected to Class II Molar, Class I canine post-surgically). We also wished to level the canted upper anterior segment, improve lip support and lip incompetence, and improve the smile esthetics.

We recommended a combined orthodontic and surgical correction for this patient. First, Surgically Assisted Rapid Palatal Expansion (SARPE) was to be used for transverse correction, followed by segmental leveling and aligning of the maxillary arch and leveling and aligning of the mandibular arch. Differential force cantilever arms were to be fabricated to upright and extrude the canted maxillary segment, and the arches prepared for 1-jaw orthognathic surgical correction and grafting at the cleft site. Following surgery, the patient's bite would be detailed and finished orthodontically by using intermaxillary elastics. Due to the

upper left peg lateral's proximity to the cleft site and minimal root surface area, it had a guarded to poor prognosis in the long term. Thus a fixed prosthesis was planned to replace the upper left lateral incisor to match the contralateral substituted canine at the conclusion of orthodontic treatment. This treatment plan was accepted by the patient and his legal guardians.

Treatment Process

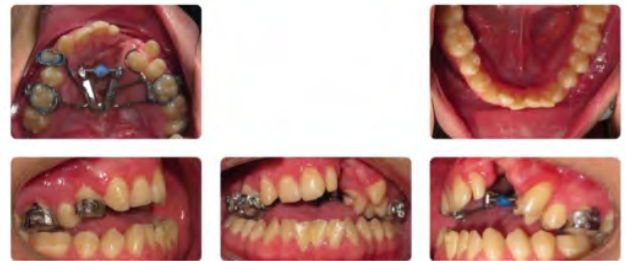

Figure 2 Post-Surgically Assisted Rapid Palatal Expansion (SARPE)

A fan-shaped RPE device was fabricated and cemented to the upper first molars and upper right first bicuspid. The patient was then referred to the Department of Oral and Maxillofacial Surgery at Columbia University CDM for SARPE treatment, which involved corticotomy and osteotomy of the maxillary and palatal bones. After one week of healing, the fan-shaped expander was activated 0.25mm two times per day and the patient was monitored on a weekly basis. After proper transverse maxillary expansion was achieved, the expansion screw was fixed (Figure 2). Prior to bonding fixed orthodontic appliances, the patient's ectopic upper left first bicuspid was removed. The patient was then bonded with upper and lower 0.022" X 0.028" slot fixed orthodontic brackets (Roth, 3M - Unitek). The upper arch was segmentally leveled and aligned as a right posterior segment (second molar to right first bicuspid), anterior segment (right cuspid to left lateral incisor), and left posterior segment (left cuspid to second molar) with a sequence of 0.016", 0.017" X 0.025", and 0.019" X 0.025" nickel titanium archwires. The lower arch was continuously leveled and aligned until 0.019" X 0.025" nickel titanium archwire. At this point an upper 0.019" X 0.025" stainless steel segmental archwire was placed in preparation for leveling the canted maxillary anterior segment. Two 0.017" X 0.025" beta titanium cantilever arms were bent and inserted bilaterally into the auxillary slots of the first molar bands. These springs were activated at differential forces (the left side receiving the stronger force) and tied in with steel ligatures just distal to the anterior segment on each respective side. Posterior intermaxillary seating elastics were used to ensure the bite did not open distal to the cuspids. These canteliever arms were re-activated every 4 weeks for approximately 4-5 months until a straight archwire could be placed (Figure 3). Once the upper and lower

Treatment of an Adult Unilateral Complete Cleft Lip and Palate Patient: A Case Report

arches could passively fit 0.019" X 0.025" stainless steel wires, surgical hooks were welded to these wires in preparation for a 2-piece maxillary advancement surgery. Pre-surgical records including progress photographs, panoramic and lateral cephalogram were taken, and the patient was referred to OMFS for final surgical workup

Discussion

The first "phase" of orthodontic treatment for most patients with transverse skeletal discrepancies is usually some form of rapid maxillary expansion. This condition is often caught by the dentist or orthodontist at a young age. It is very important that we treat these skeletal deficiencies sooner rather than later as RPE is able to induce more favorable skeletal change when done before the pubertal peak in skeletal growth. If RPE treatment is undertaken after this particular peak in skeletal growth, the changes seen from active expansion become less orthopedic and largely dentoalveolar.⁶ In instances where we need true transverse skeletal expansion when the midpalatal suture has fused, as is the case in our adult patient, Surgically Assisted Rapid Palatal Expansion (SARPE) treatment can be an alternative option. SARPE is a surgical technique that essentially involves all bone cuts required for a Le Fort I osteotomy and includes the separation of the pterygoid junction and midpalatal suture between the incisor roots. During the surgery, the expansion device is activated to achieve a 1- to 1.5-mm separation of the maxillary central incisors.⁷ Then the RPE can be continued post-surgically. In an ideal scenario, this patient would have been treated with RPE in the mixed dentition but unfortunately did not have treatment available to him at that time. Therefore the patient successfully underwent SARPE treatment to improve his maxillary transverse deficiency. Following a retentive phase of treatment, the lower arch was leveled and aligned with continuous wires and the upper arch was leveled and aligned with segmental wires. It was determined that due to the patients' hyperdivergence, open bite tendency, and amount of deflection between the anterior and posterior segments, sectional wires were more ideal than continuous wires when leveling and aligning the maxillary arch. Once the upper arch was in 0.019" X 0.025" stainless steel sectional wires, we decided to use a predictable one-couple force system to upright and extrude the maxillary anterior segment. One-couple force systems are orthodontic force systems where a cantilever spring or auxiliary wire is placed into a bracket or tube that is part of a stabilized segment and the other end is tied to a tooth or group of teeth, which are to be moved in a particular direction with a single point of force application.⁸ The advantages of one-couple appliances include high predictability of tooth movement, decreased need for re-activation, and minimization of unwanted orthodontic side effects.⁹ While a typical one-couple system such as an extrusion arch would seem appropriate for our patient, one needs to keep in mind that the maxillary anterior segment is severely canted and thus needs different amounts of force at the distal of each segment to not only extrude the teeth but level the cant concomitantly. Thus individual differential force cantilevers were bent for the right and left sides respectively. After 4-5 months of leveling the anterior segment with rest of the maxillary teeth, a continuous archwire was placed. Once

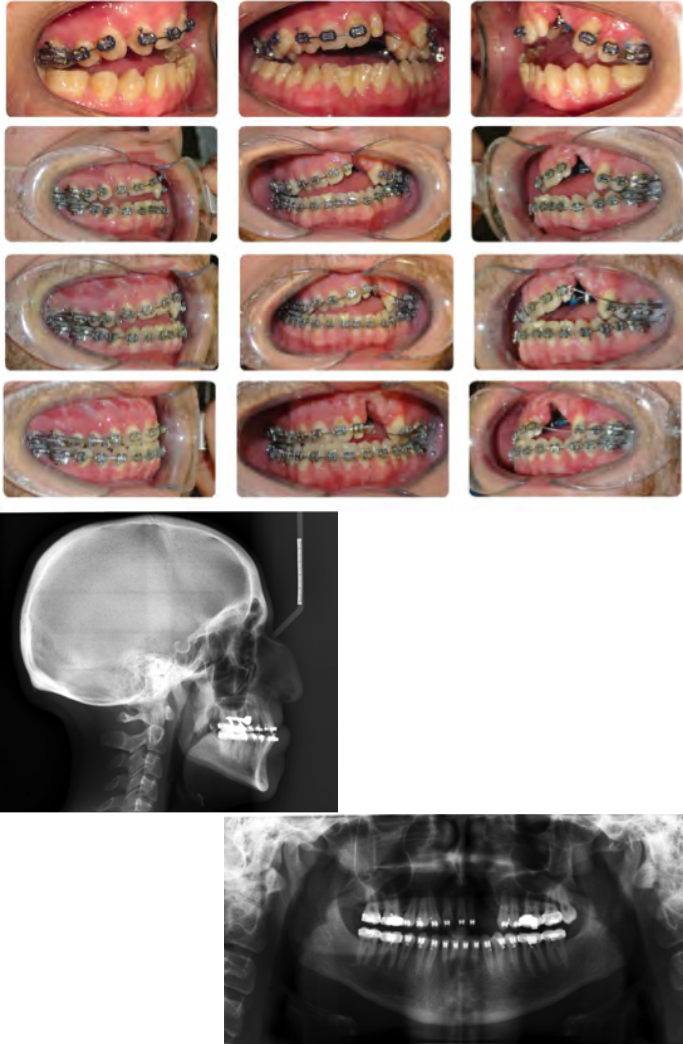


Figure 3 Treatment progress at approximately 4-month intervals. Note: beta titanium cantilever arms in the 3rd and 4th Images

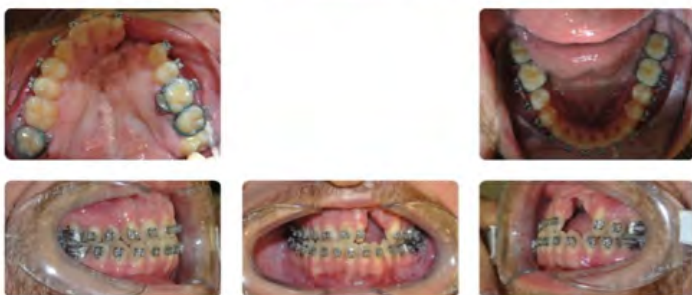

Figure 4 Pre-orthognathic surgery intra- and extra-oral records

Treatment of an Adult Unilateral Complete Cleft Lip and Palate Patient: A Case Report

continuous 0.019" X 0.025" stainless steel wires were placed, surgical hooks were added and the patient was referred to OMFS for a two-piece maxillary advancement and soft tissue and bone grafting at the fistula site. Ideally the patient should have had alveolar bone and soft-tissue grafting at age 7-9 before the eruption of the lateral incisor (if present) or canine¹⁰, however, after speaking with the oral surgeon, he was confident that a successful graft could be placed at the time of the maxillary advancement procedure.

Pre-surgically, no growth of the maxilla was observed, and a mild downward and forward growth of the mandible was seen by the slight increase of the SNB angle (Table 1). Both upper and lower arch forms were harmonized. A Class I molar, Class III canine relationship was obtained pre-surgically due mainly to the outward rotation of the buccal segments during expansion and this will be corrected to Class II molar, class I canine post-surgically. The upper incisors were torqued, proclined, and extruded relative to the palatal plane and the maxillary cant was corrected. The upper intermolar width was increased due to the surgical expansion and the upper molars felt a mild extrusion and distal movement also due to the outward rotation of the buccal segments during expansion. The lower incisors were proclined and extruded relative to the mandibular plane and there was minimal movement of the mandibular molars (Figure 5). Due to the uprighting and extrusion of the anterior maxillary segment, there was a reduction of lip incompetence and mentalis strain improving the profile and smile aesthetics. This will also improve greatly following orthognathic surgery.

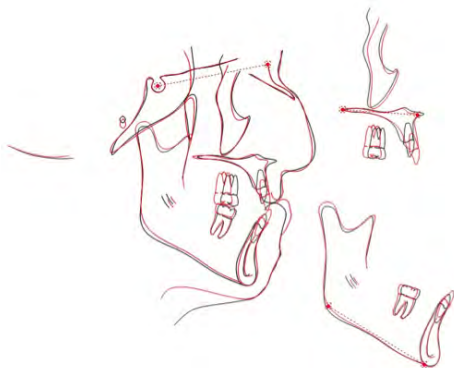


Figure 5 Superimposition of pre-treatment and pre-surgical cephalogram tracings to demonstrate skeletal and dental changes

Conclusion

The patient's chief complaint was addressed and the profile and smile aesthetics were improved. The treatment was successful in addressing the transverse discrepancy, the AP and vertical position of the maxillary incisors, closure of the open bite and leveling of the maxillary cant, and preparing the patient for maxillary surgical correction. The patient has been referred to OMFS for a two-piece maxillary

advancement and bone and soft tissue grafting for the fistula. After surgery is completed, the patient will be referred back for detailing and finishing of the bite and then will be referred to a prosthodontist for an aesthetic replacement for the upper left peg lateral incisor.

Acknowledgements

I would like to thank Dr. Aditya Chhibber, Dr. Jing Chen, Dr. June Harewood and Dr. Sidney Eisig for their invaluable knowledge and wisdom and most importantly their assistance in making a profound impact on this individual's life.

References

1. Sperber GH. *Craniofacial Development*. Hamilton, Canada: B.D. Decker INC; 2001.
2. Sperber GH. *Craniofacial Development*. Hamilton, Canada: B.D. Decker INC; 2001.
3. Jeffrey O. Bush, Rulang Jiang: Palatogenesis: morphogenetic and molecular mechanisms of secondary palate development. *Development* 139, 231-243 (2012)
4. R.E. Waterman, S.M.Meller: Alterations in the epithelial surface of human palatal shelves prior to and during fusion: A scanning electron microscopic study. *Anat. Rec* 180:111-136, 1974
5. Sperber GH. *Craniofacial Development*. Hamilton, Canada: B.D. Decker INC; 2001.
6. Tiziano Baccetti, Lorenzo Franchi, Christopher G. Cameron, and James A. McNamara Jr. (2001) Treatment Timing for Rapid Maxillary Expansion. *The Angle Orthodontist*: October 2001, Vol. 71, No. 5, pp. 343-350.
7. Chamberland, Sylvain, and William R. Proffit. "Closer look at the stability of surgically assisted rapid palatal expansion." *Journal of Oral and Maxillofacial Surgery* 66.9 (2008): 1895-1900.
8. Proffit, William R., Henry W. Fields Jr, and David M. Sarver. *Contemporary Orthodontics*. Elsevier Health Sciences, 2014. pp. 336-337
9. Lindauer, Steven J., and Robert J. Isaacson. "One-couple orthodontic appliance systems." *Seminars in orthodontics*. Vol. 1. No. 1. WB Saunders, 1995.
10. Proffit, William R., Henry W. Fields Jr, and David M. Sarver. *Contemporary Orthodontics*. Elsevier Health Sciences, 2014. p.269

Instruction for Authors

The Columbia Dental Review seeks to address topics of clinical concern. The Editorial Board welcomes articles from students, faculty, and attendings from affiliated hospitals of the College of Dental Medicine of Columbia University.

The case report should be organized in the following manner:

Abstract

The abstract summarizes the principal points of the case report and specific conclusions that may have emerged in the discussion. It should be limited to less than 250 words.

Author Information

A description of each author's degrees, titles, department, and affiliation should be given.

Information

The introduction should provide a brief description of the topic, as well as any relevant epidemiology and current opinion as documented in the literature.

Case Report

A description of the case(s), including pertinent photographs.

Discussion

A thorough review of the literature, including other reported cases that are relevant to the case(s) presented or reported.

Conclusion

Based on the present case(s) and the discussion.

References

The authors should be listed in the order in which they appear in the articles. In the case of multiple authors, all authors' names must be given.

Within the text, citations of these references should appear as follows:

Potassium channel-blockers serve as therapeutic agents to interfere with bone resorption of periodontal disease.^{1,2,3}

In the References Section the references should be listed in the order in which they were cited in the text and with the corresponding number.

To cite a journal article (in References section):

Valverde P, Kawai T, Taubman MA (2005) Potassium channel-blockers as therapeutic agents to interfere with bone resorption of periodontal disease. J Dent Res 84: 488-499.

To cite a chapter in a book (in References section):

Cowin SC, Luo G (1997) Modeling of ingrowth into implant cavities along the bone implant surface. In: Osseointegration in Skeletal Reconstruction and Joint Replacement (PI Brånemark, BL Rydevik, R Skalak, Eds) Chicago, Quintessence Publishing Co, Inc, pp 57-72.

To cite a book (in References section):

Drake RL, Vogl W, Mitchell AWM (2005) Gray's Anatomy for Students. Philadelphia, Elsevier.

To cite a website (in References section): American Dental Association. Estrogenic effects of Bisphenol A lacking in dental sealants. ADA Position Statement. 2000. Available at: "www.ada.org/prac/position/seal-est.html". Accessed April 4, 2005.

Figures and Manuscripts

Image files and manuscripts will be accepted on CD with author's name printed on the CD. Image files should be of high-resolution quality and should be submitted in TIFF, TIF, TGA, GIF or JPEG format. A brief caption in the order in which they are mentioned should be submitted on a separate page. The manuscript should not exceed 20, letter size, double-spaced pages and should be written in a text editor, preferably Microsoft® Office Word. Both, the manuscript and figures, should be submitted in printed format as well as on CD.